

# Accuracy Assessment of 3D Tooth Reconstruction with Novel Segmentation Technique

Thanatchaporn Permwatanachai<sup>1</sup>, Kanit Dhanesuan<sup>1</sup>

<sup>1</sup>Department of Oral and Maxillofacial Surgery, Faculty of Dentistry, Chulalongkorn University, Bangkok, Thailand

## Abstract

Nowadays, in modern medicine, three-dimensional (3D) reconstruction uses innovative new applications by building cost-effective patient-specific surgical models and prostheses. Concurrently, 3D reconstruction is useful in dental and maxillofacial disciplines for pre-operative planning and surgical simulation. During the 3D reconstruction process, one of the significant procedures is segmentation, which involves extracting interesting structures from undesirable surroundings. In this case, if the digital segmentation is inaccurate, the physical model generated by the virtual model will not properly represent the anatomy of the structure, resulting in a discordance between the treatment plan and the outcome. The study aims to assess the segmental accuracy of the new threshold-based semi-automatic segmentation method for establishing 3D tooth reconstruction from cone-beam computed tomography (CBCT). Ten extracted teeth and corresponding pre-existing CBCT images were collected for this experimental study. The physical data of each extracted tooth was gathered as tooth length and volume, which were measured by an electronic digital caliper and a densitometer for solids, respectively. The new threshold-based semi-automatic segmentation method was performed by InVesalius software to establish 3D tooth reconstruction from corresponding pre-existing CBCT images. The outcomes were measured through linear (deviation of the tooth length) and volumetric (percentage of volume alteration) measurements between the 3D model and extracted tooth, using measurement tools in the Meshmixer software. The Wilcoxon signed rank test was used to investigate all parameters. The results revealed no significant difference in size between the 3D reconstruction and physical teeth in both linear and volumetric measurements. Moreover, the accuracy of the segmental procedure in the linear and volumetric assessments is 97.44% and 94.95%. In conclusion, the new segmental technique from this study exhibits good accuracy. However, further investigation in clinical application of the printing models established from this new method is recommended to confirm its efficacy.

**Keywords:** 3D reconstruction, 3D tooth reconstruction, Accuracy, Segmentation, Thresholding segmentation

**Received Date:** Mar 31, 2023

**Revised Date:** May 12, 2023

**Accepted Date:** Jul 28, 2023

doi: 10.14456/jdat.2023.26

**Correspondence to:**

Kanit Dhanesuan, Department of Oral and Maxillofacial Surgery, Faculty of Dentistry, Chulalongkorn University, 34 Henri-Dunant Road, Pathumwan, Bangkok 10330, Thailand. Email: kanit.d@chula.ac.th

## Introduction

Advances in craniofacial imaging and image acquisition techniques, such as CBCT images, had improved our understanding of anatomical structures and probable anatomical differences. 3D reconstruction images from CBCT had been the best option for evaluating and treating surgical problems in dental and craniofacial surgery, as well as a variety of other specialties.<sup>1</sup> Some examples assisted in the development of a root analog implant designed for immediate implantation<sup>2</sup>, creating a surgical guide for implant surgery<sup>3</sup>, or simulating and navigating oral and maxillofacial surgery.<sup>4,5</sup>

During the 3D reconstruction process, one of the significant procedures was segmentation, which involved extracting the structures that would be created in the 3D model from undesirable surrounding structures.<sup>6,7</sup> Segmentation can be classified into three approaches: manual, automatic, and semi-automatic segmentation. First, the manual approach was user-dependent and done layer by layer with software that groups all the layers together to rebuild the 3D volume, which was a time-consuming procedure and required the skill of an operator.<sup>8</sup> Second, automatic method, in which the software automatically selected the interested region and excluded other nearby structures after setting the threshold interval. Because it was time-saving and less operator-reliant, this technique had the benefit of processing lots of data.<sup>9,10</sup> However, the lack of spatial resolution and contrast in the image was the key challenge in this type of segmentation.<sup>9,11</sup> And the last one, semi-automatic segmentation was a computerized (hybrid) approach. In this case, the process typically began with two user-driven interactive stages, including the placement of initial seed areas in all three directions and selecting a threshold interval (Hounsfield units) to provide texture and background data for the program.<sup>8</sup>

By the way, grayscale intensities would be displayed by the selection. When the range was not properly defined, the anatomical structure of interest might be distorted, causing undesirable dimensional changes.<sup>7</sup> In

the case of inaccurate digital segmentation, the physical model generated by the 3D virtual model would not properly represent the anatomy of the structure, resulting in a discordance between the treatment plan and the outcome.<sup>14</sup>

The accuracy of the segmentation technique, particularly the threshold selection procedure, was the critical element that could possibly affect the quality of measurements in the 3D reconstructions. Whereas 3D reconstruction has innovative new applications by building cost-effective patient-specific surgical models and prostheses in modern medicine as well as in dental and maxillofacial disciplines for pre-operative planning and surgical simulation.<sup>12,13</sup> There are several commercial and open-source software packages with various tools available on the market. InVesalius, one of the free open-source 3D reconstruction software applications<sup>16</sup>, as well as Meshmixer, one of the free open-source 3D model graphical information processing software<sup>15</sup>, have been utilized by many research projects.

Furthermore, the indicated mask over the examined image, in the threshold-based segmentation technique of the InVesalius software program, was obtained from a medical CT. While the range of grayscale values obtained from dental CT images, which are more practically used in dentistry, were not similar. Thus, it was necessary to use manual control to adjust the threshold values together, focusing on the entire anatomical outline in all slices, as the new segmental method.

Therefore, the aim of this study was to assess the segmentation accuracy of the new threshold-based semi-automatic tooth segmentation technique for establishing 3D tooth reconstruction from CBCT imaging. The null hypothesis was that the size of the 3D reconstruction model did not differ from the size of the physically extracted tooth. The expected benefits of this study could include aid in the diagnosis, treatment plan, and enable the creation of patient-specific models or surgical guides, which could

be assisted in preoperative planning and intraoperative navigation. These tools could improve surgical outcomes, as well as reduce operation time, and the risk of complications.

## Materials and methods

This experimental study was conducted from October 2022 to February 2023 at the Department of Oral and Maxillofacial Surgery, Faculty of Dentistry, Chulalongkorn University. The workflow of this study was presented in Figure 1.

The sample size of  $n = 4$  was calculated by G\*Power 3.1, referring to the previous study (Park *et al.*, 2020). The samples were collected and categorized into two groups: maxillary and mandibular teeth. Thus,

the total sample size required was five for each group, including approximately 10 % compensation for errors.

The protocol was approved by the Human Research Ethics Committee of the Faculty of Dentistry, Chulalongkorn University (HREC-DCU 2022-077).

### Sample selection

Patients who were referred for tooth removal with pre-existing radiographic data (CBCT imaging) were included in the study. Patients whose teeth had fractures were excluded. A total of ten extracted teeth from five patients were included, comprising five maxillary and five mandibular teeth. All participants were informed about the research details and provided written consent.

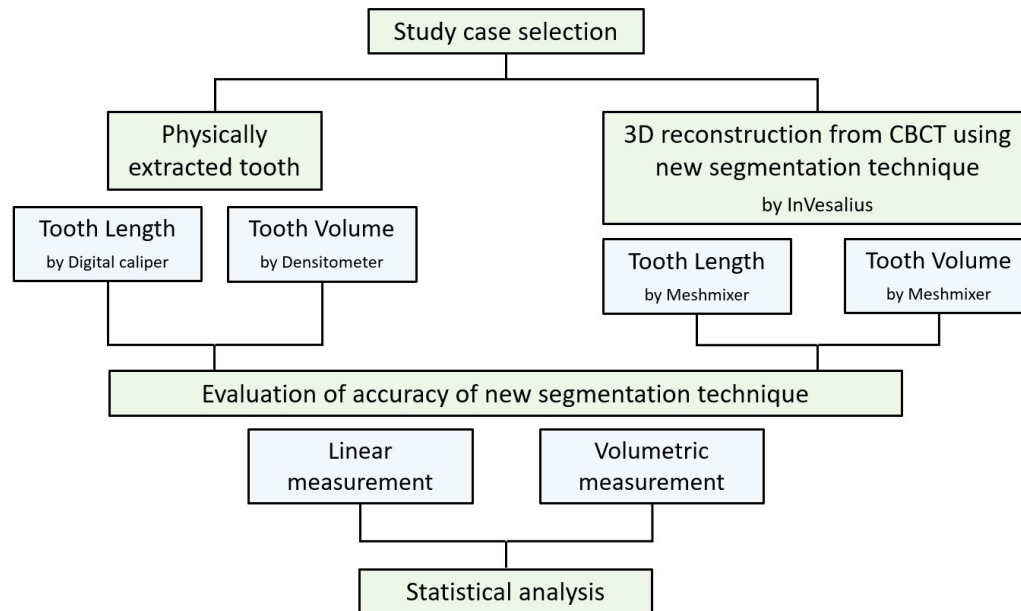
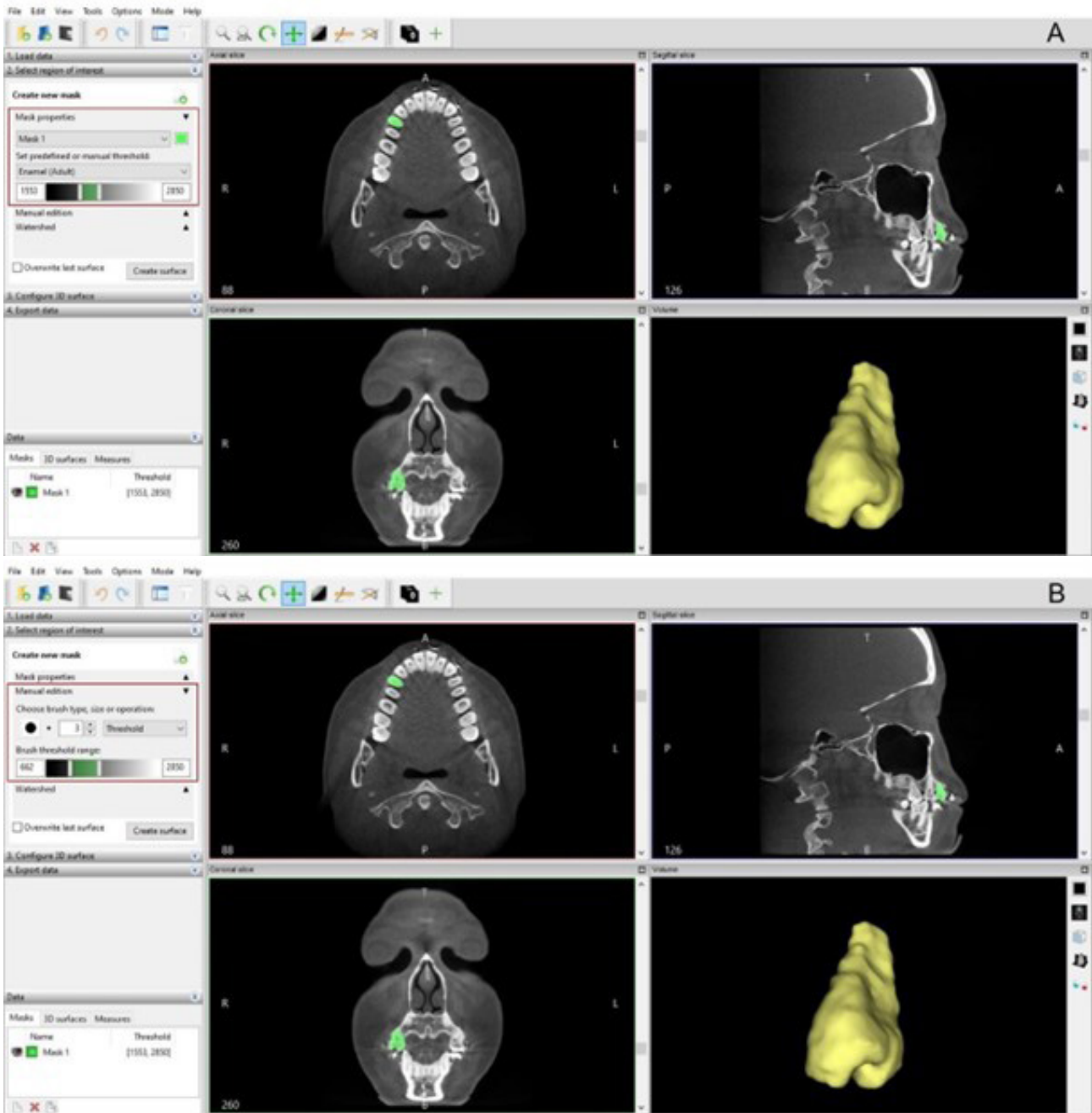


Figure 1 Study workflow

### Study methods

The physical data of all extracted teeth were collected as a tooth length and volume, which were measured by an electronic digital caliper (in millimeters) and a densitometer for solids (in cubic millimeters), respectively. All corresponding pre-existing CBCT images were segmented by the InVesalius software program using a new threshold-based semi-automatic segmentation technique. The procedure was carried out by importing the radiographic data with 1:2 slices re-arrangement, followed by creating

a selection mask using the enamel's predefined threshold value range (Fig. 2A) together with manual adjustment for the desired threshold using the "Brush" and "Brush threshold range" tools (Fig. 2B). The selection mask was focused on the entire anatomical outline of the tooth layer by layer, as the new segmentation technique. Finally, the 3D virtual model was isolated in the visualization window using the "Splitting disconnected surfaces: select the largest surface option" tool and exported into STL format.



**Figure 2** New threshold-based semi-automatic segmentation technique by InVesalius software

A: First step of selection mask creation by enamel's predefined threshold value range in mask property tab

B: Second step of selection mask creation by manual adjustment using "Brush" and "Brush threshold range" tools in manual edition tab

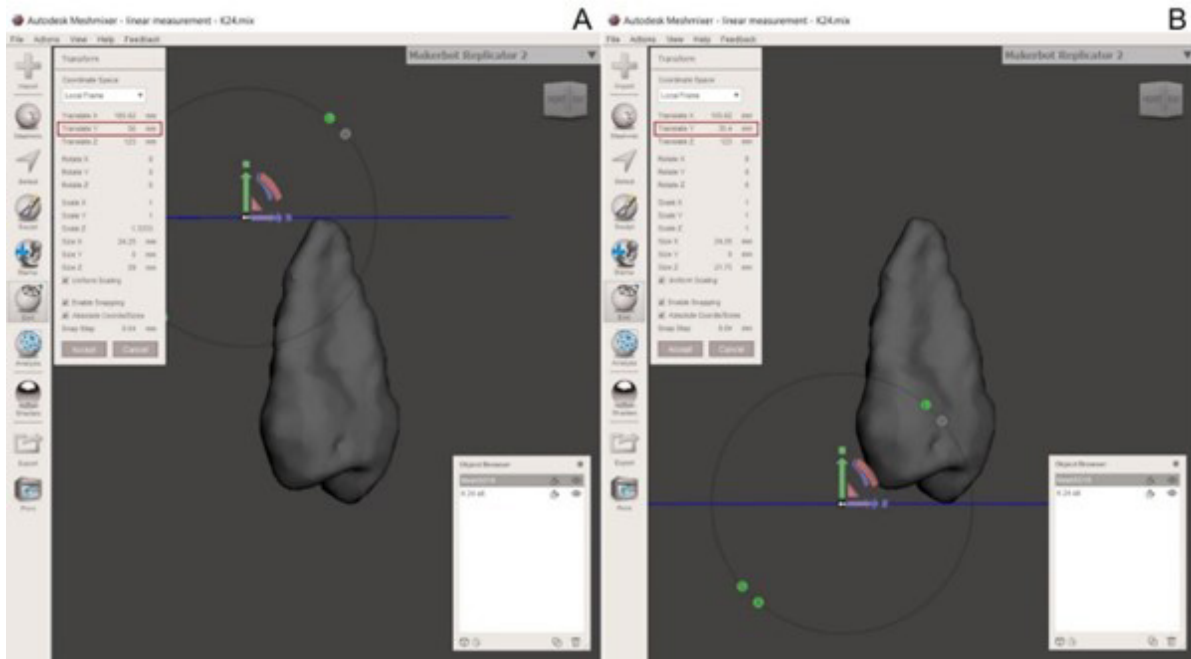
## Assessments

Two parameters were used for the measurement of segmental procedure accuracy: linear deviation and volumetric deviation. The linear deviation was defined as the difference in the length (along the cusp tip or incisal

edge to the root apex) between each couple of the 3D reconstruction model and the corresponding physically extracted tooth. The volumetric deviation was assessed by the volume change between the 3D reconstruction model and the corresponding physically extracted tooth.

All parameters were measured in the Meshmixer software program. In linear measurement, the length was scaled against two planes that contact the most superior and inferior surfaces of the model (the differences in the Y-axis positions), using “Edit” and “Transform” tools (Fig. 3).

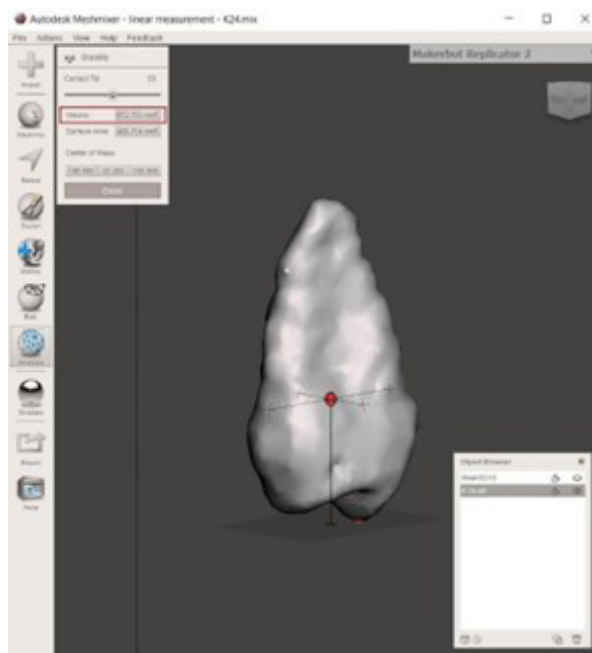
The procedures were performed three times by a single examiner, to minimize errors that can arise with different investigators. Whereas, volumetric measurement was automatically determined by “Analysis” and “Stability” tools (Fig. 4).



**Figure 3** Linear measurement by Meshmixer software

*A: The plane that contacted to the most superior aspect of model (root apex)*

*B: The plane that contacted to the most inferior aspect of model (cusp tip) Tooth length was scaled by the difference in the Y-axis position of these two planes*



**Figure 4** Volumetric measurement by Meshmixer software

## Statistical analysis

All ten samples were assessed, and statistical analysis was executed using the statistical package for the social sciences (SPSS version 28) software program. All data were analyzed and compared using a Wilcoxon signed rank test. The intra-observer agreement was performed to qualify the results (ICC = 0.986), three samples were selected and analyzed twice by the main observer with a two-week interval.

## Results and discussions

### Results

The accuracy of segmental procedures in linear measurement was shown in Table 1. The linear deviation between the 3D-reconstructed model and the physically

extracted tooth in tooth length in terms of percentage was examined.

While Table 2 showed the accuracy of segmental procedures in volumetric measurement. The volumetric deviation between the 3D-reconstructed model and the physically extracted tooth in terms of percentage was executed.

The results revealed that no statistically significant difference was found when both the linear and volumetric measurements were considered ( $P = 0.799$  and  $P = 0.878$ , respectively). The correlation was also discovered when the linear and volumetric deviations were taken into account (Pearson correlation coefficients:  $r = 0.995$  and  $r = 0.988$ , respectively). As well, the accuracy of the segmental procedures was 97.44 % in linear measurement and 94.95 % in volumetric measurement (Table 3).

**Table 1** Accuracy of segmental procedures in linear measurement

Parameters	Linear measurement (mm)		
	3D model	Physical tooth	Linear deviation (%)
Tooth #1	10.66	9.70	9.89
Tooth #2	11.24	11.57	2.76
Tooth #3	20.89	20.76	0.62
Tooth #4	20.61	20.79	0.81
Tooth #5	22.36	21.48	4.09
Tooth #6	18.09	18.66	3.00
Tooth #7	20.72	20.85	0.57
Tooth #8	20.84	20.56	1.36
Tooth #9	23.99	24.35	1.47
Tooth #10	24.32	24.68	1.41

**Table 2** Accuracy of segmental procedures in volumetric measurement

Parameters	Volumetric measurement (mm <sup>3</sup> )		
	3D model	Physical tooth	Volumetric deviation (%)
Tooth #1	103.71	106.2	2.33
Tooth #2	256.64	246.0	4.32
Tooth #3	651.71	693.2	5.98
Tooth #4	672.70	700.1	3.91
Tooth #5	700.76	652.6	7.37
Tooth #6	976.22	933.5	4.57
Tooth #7	635.61	621.1	2.33
Tooth #8	629.52	607.4	3.64
Tooth #9	527.79	560.8	5.88
Tooth #10	525.88	579.6	9.26



**Table 3** Statistical analysis of novel segmentation technique accuracy

	Parameters	Mean	Minimum	Maximum	P value	Pearson correlation	Accuracy (%)
Linear	3D model	19.37	10.66	24.32	0.799	0.995	97.44
	Physical tooth	19.34	9.70	24.68			
Volumetric	3D model	568.05	103.71	976.22	0.878	0.988	94.95
	Physical tooth	570.05	106.20	933.50			

## Discussions

There are a lot of software programs available on the market for analyzing digital imaging and communications in medicine (DICOM). However, creating CBCT-based segmentation reconstruction is still not a typical process in dental practice. According to the manufacturer, the software is difficult to use, requires higher computer specification, and is licensed by the company, resulting in higher financial expenditures. Other free, open-source DICOM viewers are also available online. Because the majority of them involve particular segmentation procedures and are developed in academic settings or by a small research group, physicians may not be aware of these free, open-source alternatives.<sup>10</sup> The InVesalius software program is one of the free open-source medical software that generates the 3D reconstruction models corresponding to the anatomical components through automated thresholding, image segmentation, mesh creation, volume rendering, and enabling 3D printing.<sup>16</sup> Meanwhile, the Meshmixer software program is also a free open-source medical software that performs the inspection, analysis, modification, and pre-processing of virtual models before printing.<sup>15</sup> These programs are compatible with low-cost machines and various operating systems.

The segmentation technique is defined as the virtual separation of an anatomical region with the elimination of any non-interesting features to improve visibility and analysis.<sup>17</sup> Tooth segmentation from CBCT images is challenging according to the following factors: 1) When a CBCT is obtained under natural occlusion, it is difficult to distinguish a lower tooth from the opposing upper tooth along its occlusal surface due to the lack of grayscale changes.<sup>11</sup> 2) Similarly, due to their extremely comparable densities, it is difficult to distinguish a tooth

from its surrounding alveolar bone. 3) And adjacent teeth with similar shapes tend to confuse attempts to distinguish distinct tooth instances. Therefore, it is difficult to achieve successful tooth segmentation by relying on variations in the intensity of CBCT images alone.<sup>18</sup> In this way, corresponding grayscale intensities (e.g., bone tissue attenuation) should be displayed by the selection. In the case where the range is not adequately defined, the structures of interest might be thicker or thinner, causing undesirable dimensional changes.<sup>7</sup>

The previous experimental study found that the linear measurements made on mandibular 3D models obtained using standard preset thresholds were reliable and accurate.<sup>19</sup> This study also examines the segmentation accuracy of the new threshold-based semi-automatic method for establishing 3D tooth reconstruction from CBCT imaging through the assessment of the linear and volumetric measurements.

The outcome of this study showed no difference in size between the new segmental technique 3D reconstruction model and the physically extracted tooth, which is consistent with a prior study, which indicated that the accuracy of 3D reconstruction was higher in the case that a high enough number of teeth remained and the set gray value reconstructed the shape of the teeth properly.<sup>20</sup>

To comment on the difference in size, according to the means of 3D models and physical teeth on linear assessment, it is likely larger, and conversely, on volumetric assessment, it is likely smaller. Consequently, both parameters' measurements presented no significant differences, so the 3D models generated by the new segmentation method could be helpful in preoperative

planning or intraoperative navigation to improve surgical outcomes, reduce operation time, and decrease the risk of complications.

However, the limitation of this study is that it is an *in vitro* study performed only in the software program without printing out physical models, which may provide valuable information about the success or limitations associated with use in a clinical setting. Future research may consider more confounding factors that might affect the segmentation procedure, such as the location of the region of interest (maxilla or mandible) or anatomical variation (single root or multiple root). As well as the clinical application of the printing models to determine the full potential of this new segmentation method.

## Conclusions

The new threshold-based semi-automatic segmentation method was a promising approach for establishing 3D tooth reconstruction from CBCT images. The study indicated that this method demonstrated good accuracy and had no significant difference in size between the 3D tooth reconstruction and physical teeth, which suggested that it could be a cost-effective and efficient approach for pre-operative planning and surgical simulation in dental and maxillofacial disciplines. However, the study also recommended further investigation with a larger sample size to confirm the efficacy of the method and ensure that it could be effectively applied in a clinical setting.

## Acknowledgements

The author would like to express sincere gratitude to Assist. Prof. Kanit Dhanesuan, my research advisor, for providing valuable guidance and feedback throughout this project. In addition, I also sincerely appreciate the support of all participants, all staff at the Department of Oral and Maxillofacial Surgery, Faculty of Dentistry, Chulalongkorn University, as well as Assoc. Prof. Dr. Nutthita Chuankrerkkul, staff at the Metallurgy and Materials Science Research Institute, Chulalongkorn University, in their contributions to this project.

## References

1. Anderson P, Yong R, Surman T, Rajion Z, Ranjitkar S. Application of three-dimensional computed tomography in craniofacial clinical practice and research. *Aust Dent J* 2014;59:174-85.
2. Mangano FG, Cirotti B, Sammons RL, Mangano C. Custom-made, root-analogue direct laser metal forming implant: a case report. *Lasers Med Sci* 2012;27(6):1241-5.
3. Shen P, Zhao J, Fan L, Qiu H, Xu W, Wang Y, et al. Accuracy evaluation of computer-designed surgical guide template in oral implantology. *J Craniomaxillofac Surg* 2015;43(10):2189-94.
4. Eggers G, Mühling J, Hofele C. Clinical use of navigation based on cone-beam computer tomography in maxillofacial surgery. *Br J Oral Maxillofac Surg* 2009;47(6):450-4.
5. Orentlicher G, Abboud M. Guided surgery for implant therapy. *Oral Maxillofac Surg Clin North Am* 2011;55(4):715-44.
6. Choi JY, Choi JH, Kim NK, Kim Y, Lee JK, Kim MK, et al. Analysis of errors in medical rapid prototyping models. *Int J Oral Maxillofac Surg* 2002;31(1):23-32.
7. Engelbrecht WP, Fourie Z, Damstra J, Gerrits PO, Ren Y. The influence of the segmentation process on 3D measurements from cone beam computed tomography-derived surface models. *Clin Oral Investig* 2013;17(8):1919-27.
8. Chen X, Xu L, Yang Y, Egger J. A semi-automatic computer-aided method for surgical template design. *Sci Rep* 2016;6(1):1-18.
9. Wang L, Li S, Chen R, Liu S-Y, Chen J-C. An automatic segmentation and classification framework based on PCNN model for single tooth in MicroCT images. *PLoS One* 2016;11(6):e0157694.
10. Lo Giudice A, Ronsivalle V, Grippaudo C, Lucchese A, Muraglie S, Lagravère MO, et al. One step before 3D printing—Evaluation of imaging software accuracy for 3-dimensional analysis of the mandible: A comparative study using a surface-to-surface matching technique. *Materials (Basel)* 2020;13(12):2798.
11. Ji DX, Ong SH, Foong KWC. A level-set based approach for anterior teeth segmentation in cone beam computed tomography images. *Comput Biol Med* 2014;50:116-28.
12. Schendel SA, Hatcher D. Automated 3-dimensional airway analysis from cone-beam computed tomography data. *J Oral Maxillofac Surg* 2010;68(3):696-701.
13. Almaqrami B-S, Alhammadi M-S, Cao B. Three dimensional reliability analyses of currently used methods for assessment of sagittal jaw discrepancy. *J Clin Exp Dent* 2018;10(4):e352.
14. Nucera R, Lo Giudice A, Bellocchio M, Spinuzza P, Caprioglio A, Cordasco G. Diagnostic concordance between skeletal cephalometrics, radiograph-based soft-tissue cephalometrics, and photograph-based soft-tissue cephalometrics. *Eur J Orthod* 2017;39(4):352-7.



15. Paramasivam V, Singh G, Santhanakrishnan S. 3D printing of human anatomical models for preoperative surgical planning. *Procedia Manuf* 2020;48:684–90.
16. Khan M. Estimating accuracy of the CBVT InVesalius Imaging Software to measure the volume of simulated periapical defects in a human cadaver mandible 2018.
17. Fastuca R, Lorusso P, Lagravère MO, Michelotti A, Portelli M, Zecca PA, *et al.* Digital evaluation of nasal changes induced by rapid maxillary expansion with different anchorage and appliance design. *BMC Oral Health* 2017;17(1):1-7.
18. Cui Z, Li C, Wang W, editors. ToothNet: automatic tooth instance segmentation and identification from cone beam CT images. Proceedings of the IEEE/CVF Conference on Computer Vision and Pattern Recognition; 2019.
19. Poleti ML, Fernandes TMF, Moretti MR, Puzinato LR, Slaviero TVS, Rubira-Bullen IRF. Reliability and accuracy of automatic segmentation of mandibular 3D models on linear measurements. *Clin Oral Investig* 2021;25(11):6335-46.
20. Park S-W, Yoon RG, Lee H, Lee H-J, Choi Y-D, Lee D-H. Impacts of Thresholds of Gray Value for Cone-Beam Computed Tomography 3D Reconstruction on the Accuracy of Image Matching with Optical Scan. *Int J Environ Res Public Health* 2020;17(17):6375.