

The Comparisons of Maxillary Anterior Teeth Positions and Smile Appearances After Orthodontic Treatment Between Four First Premolar Extraction and Nonextraction in Class I Crowding Cases

Teerapat Wongmaneerung¹, Wikanda Khemaleelakul¹, Virush Patanaporn¹

¹Department of Orthodontics and Pediatric Dentistry, Faculty of Dentistry, Chiang Mai University, Chiang Mai, Thailand

Abstract

The purpose of this study was to compare maxillary anterior teeth positions and smile appearances between four first premolar extraction and nonextraction in Class I crowding cases. Forty-one participants with moderate Class I crowding who had finished orthodontic treatment were recruited and divided into two groups. The first group consisted of 21 participants who had finished nonextraction orthodontic treatment, and the other group consisted of 20 participants who had finished orthodontic treatment with four first premolars extracted. Smiling pictures in frontal and lateral positions of the participants were taken. In part one, the maxillary anterior teeth positions and smile appearances were measured and analyzed. In part two, the smile esthetic of the cropped frontal smiling pictures was rated by three certificated board orthodontists and ten laypersons using the visual analog scale (VAS), and then the VAS scores were compared between the nonextraction and the extraction groups. In the assessment using smiling pictures, the ratio of the distance between the maxillary dental midline and the distal surface of the maxillary canine to the distance between the maxillary dental midline and the angle of the mouth, as well as the ratio of the distance between the left and right maxillary canine cusp to the distance between the left and right alar of the nose in four first premolar group, was significantly higher than in the nonextraction group. The difference between the horizontal distance of the left and the right alar of the nose to left and right maxillary canine cusp tip in the four first premolar extraction group was significantly lower than the nonextraction group. Maxillary canines in the four first premolar extraction group are significantly closer to the alar of the nose and the labial commissures than the maxillary canines in the nonextraction group. Maxillary teeth positions and smile appearances evaluated from the other smile parameters did not differ significantly between the two groups.

Keywords : Nonextraction orthodontic treatment, Four first premolar extraction orthodontic treatment, Maxillary anterior teeth positions

Received Date: Jun 12, 2023

Revised Date: Aug 15, 2023

Accepted Date: Sep 25, 2023

doi: 10.14456/jdat.2024.1

Correspondence to :

Virush Patanaporn , Department of Orthodontics and Pediatric Dentistry, Faculty of Dentistry, Chiang Mai University, Chiang Mai 50200, Thailand. Tel: 098-749-7856

Introduction

The three components of a smile are lip framework, gingival tissue, and dentition. Each component is important in smile attractiveness.¹ Extraction treatment is one of the several methods to gain space for dental crowding treatment.² It is probable that this approach could adversely affect the attractiveness of a smile such as widening buccal corridors or narrowing dental arches.³ However, nonextraction methods such as an arch expansion or incisors protrusion are other alternatives to treat dental crowding.² These nonextraction methods, nevertheless, seem to flare the incisors crown labially resulting in a flat smile arc and less incisal showing.⁴ Extraction guidelines for alignment stated that 5 to 9 mm of crowding could be treated by either extraction or nonextraction treatment.⁵ In order to evaluate the treatment outcome in respect to the smile esthetics, several studies measure distances, ratios, and angles from frontal smile pictures to assess the outcome in precise numbers.⁶⁻⁸ Alternatively, satisfaction of smiles can also be calculated from esthetic scores given by participants.^{9,10} The aim of this study is to compare the maxillary anterior teeth position, smile appearance, and smile esthetics measured by the VAS score after orthodontic treatment between four first premolar extraction and nonextraction in moderate Class I crowding cases by using the following parameters: canine position, upper dental midline, upper lip length and upper dental display, smile arc ratio and smile arc type, buccal corridor percentage, gingival exposure, smile symmetry, and the VAS score from board certified orthodontists and laypersons.

Materials and Methods

This study was approved by the Human Experimentation Committee, Faculty of Dentistry, Chiang Mai University (No. 69/2563). The participants are patients with moderate Class I crowding who underwent orthodontic therapy with four first premolar extraction or nonextraction. The sample size was calculated from G power program version 3.1.9.7 to reach 80% statistical power by using a test for difference between two independent means, with

a significance level of 0.05 and effect size equal to 0.91 based on data of pilot study. The calculated sample size was 20 participants per group. In the nonextraction group, there are 21 participants which consist of five males and 16 females. The ages of the participants in the nonextraction group ranged from 15 to 29 years old (mean 21.76 ± 3.83 years old). There are 20 participants which consist of six males and 14 females in the four first premolar extraction group. The ages of the participants in the four first premolar extraction group ranged from 16 to 28 years old (mean 21.85 ± 3.64 years old).

All participants comply with the features

1. Participants had dental Class I crowding (5-9 mm) with all 28 permanent teeth from upper and lower left second molar to right second molar before their orthodontic treatments. Third molars are disinterested.

2. For the nonextraction group, participants finished their orthodontic treatments with Class I canine relationships and still have all 28 permanent teeth. Third molars are disinterested.

3. For the extraction group, participants finished their orthodontic treatments with Class I canine relationships with all four first premolars extracted and they have 24 permanent teeth. Third molars are disinterested.

4. Participants have regularly applied retainers after finishing their orthodontic treatment.

Exclusion criteria are participants with a history of facial trauma, denture wearing or prosthesis implant, dental anomalies, congenital missing teeth, cleft lip or cleft palate, miniscrew placement, or a gingival display of 4 mm or more (gummy smile).

Two post-treatment pictures of each participant were taken in the frontal and the lateral positions while they smiled. A nasal positioner and ear rods of an extraoral x-ray machine (NewTom GiANO 3D) were applied on each participant to maintain the position of their heads in the frontal position. A ruler was attached to the nasal positioner. OLYMPUS E-M10 with OLYMPUS AF Macro 60 mm 1:2.8, F5 Aperture, Speed shutter 1/5, ISO Auto were used to

take pictures with a tripod. The participants were instructed to sit on an adjustable chair. The position of the chair was then adjusted until the participants' ears were properly positioned with the ear rods and nasal positioner. Participants were instructed to smile with a "maximum smile and squinting eyes". The first picture was taken when the participants smiled.

In the lateral position, pictures were taken while participants were in a natural head position. They sat on the movable chair and looked at their eyes in the mirror placed in front of them. The participants held a ruler below

their chin. The second picture was taken when the participants gave the instructed smiles.

The use of Adobe Photoshop CC 2019 software allowed for precise sizing of the pictures of the participants' faces to match their actual size. This was accomplished using rulers, with one attached to the nasal positioner in a frontal position and the other held below the participants' chins in a lateral position. The smiling frontal pictures were rotated to the parallel interpupillary line with a horizontal plane. Once in this position, various points and lines were manually plotted as shown below (Fig. 1).

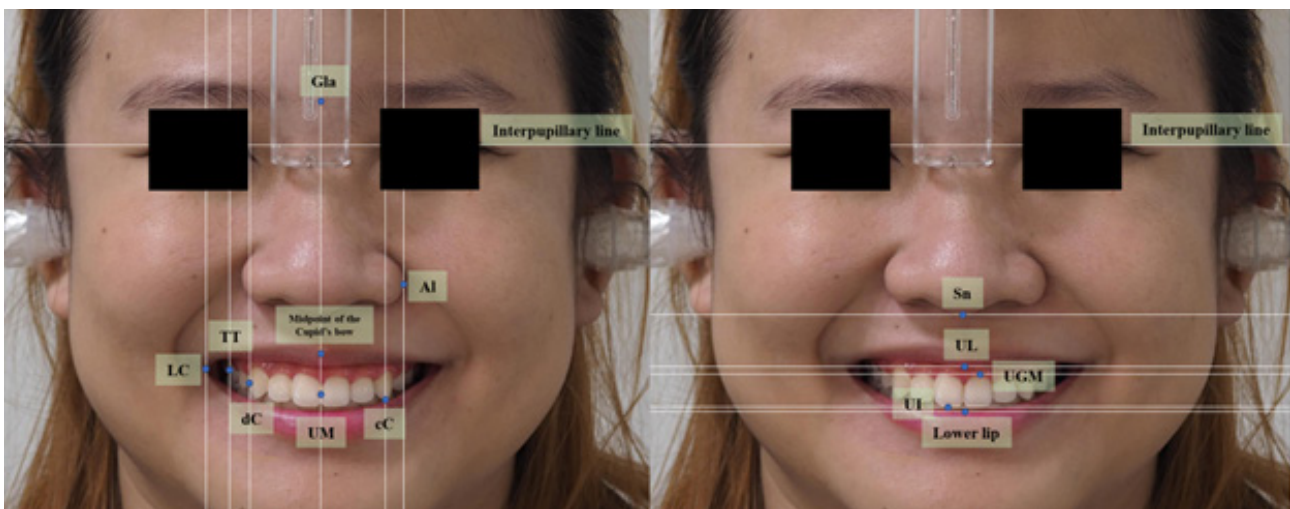

Figure 1 Points and lines plotted in frontal position picture

1. Facial midline (FM) is a line drawn through the midpoint of the soft tissue glabella to the midpoint of the upper lip's cupid's bow.

2. Gla (Glabella) is the point above the nasion and between the eyebrows.

3. Sn (Subnasale) is the midpoint on the nasolabial soft tissue contour between the columella crest and the cutaneous portion of the upper lip.

4. UM (Upper dental midline) is the vertical line drawn through the contact between the mesial surface of central incisors. This line is parallel to the facial midline.

5. dC (Distal surface of canine) is the point located at the most distal surface of a canine.

6. LC (Outer labial commissure) is the point where the vermilion border of the upper lip meets that of the lower lip.

7. TT (Terminal tooth) is the point located at the most distal surface of the last visible tooth.

8. cC (Cusp of canine) is the point located at the cusp tip of a canine.

9. AI (Alar of nose) is the point located at the most lateral surface of the nose.

10. UGM (Upper gingival margin) is the most apical gingival margin of maxillary central incisors

11. UL (Lower border of upper lip) is the midpoint of the inferior border of the upper lip.

12. UI (Upper incisal edge level) is the incisal edge of the maxillary central incisors.

The ratios, distances, and angles of the pictures will be measured based on the landmarks described above, using the specified method outlined below.

1. Canine position

1.1 Ratio of the distance between the maxillary dental midline (UM) and the distal surface of the maxillary canine (dC) to the distance between the maxillary dental midline and the angle of the mouth (LC), or UM-dC/UM-LC (Fig. 2A)

1.2 Ratio of the distance between the right maxillary canine cusp tip (RcC) and the left maxillary canine cusp tip (LcC) to the distance between the right alar of the nose (RAL) and the left alar of the nose (LAI) or RcC-LcC/RAL-LAI (Fig. 2B)

1.3 The difference between the horizontal distance of the right alar of the nose (RAL) and the left

alar of the nose (LAI) to the right maxillary canine cusp tip (RcC) and the left maxillary canine cusp tip (LcC) or (RAL-LAI) - (RcC-LcC) distance (Fig. 2B)

2. Upper dental midline

The horizontal distance between the upper dental midline (UM) and the facial midline (FM), or UM-FM.

3. Upper lip length and upper dental display

Ratio of the distance between the base of the nose (Sn) to the lower border of the upper lip (UL) and the distance between the base of the nose to the incisal edge of the maxillary central (UI), or Sn-UL/Sn-UI (Fig. 3).

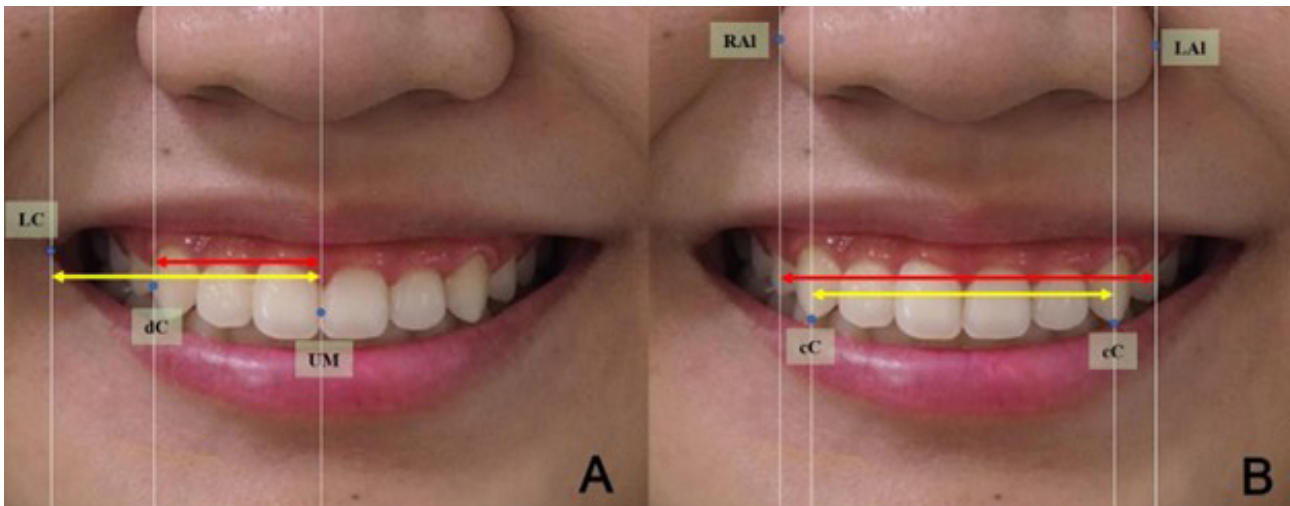


Figure 2 (A) The red line indicates the distance between maxillary dental midline and distal surface of maxillary canine (UM-dC). The yellow line illustrates the distance between maxillary dental midline and angle of mouth (UM-LC). (B) The yellow line shows the distance between the right maxillary canine cusp tip to the left maxillary canine cusp tip (RcC-LcC). The red line shows the distance between the right alar of the nose to the left alar of the nose (RAL-LAI).

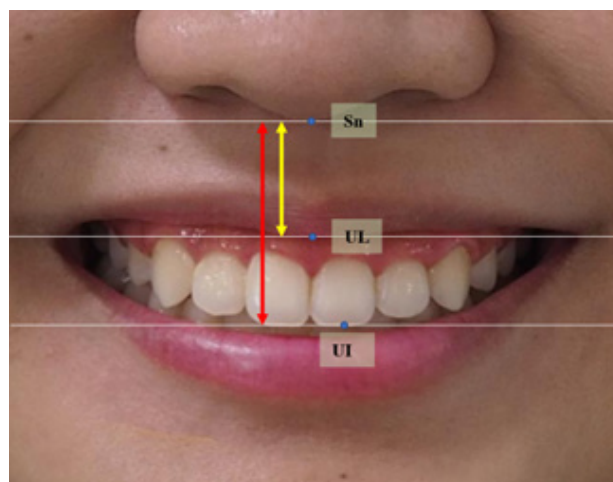


Figure 3 The yellow line indicates distance from the base of the nose to the lower border of the upper lip (Sn-UL). The red line indicates distance from the base of the nose to the incisal edge of the maxillary central incisors (Sn-UI).

4. Smile arc ratio and smile arc type

4.1 Smile arc ratio is the ratio between the distance of the maxillary incisor edge to the intercanine connecting line and the distance of the lower lip to the intercanine connecting line (Fig. 4A).

4.2 Smile arc type is categorized into three different types

Parallel smile arc defines that the maxillary incisal edges and the canine cusp tips had parallel curvature relative to the lower lip line. (Fig. 5A)

Flat smile arc defines that the maxillary incisal edges and the canine cusp tips had no curvature relative to the lower lip line. (Fig. 5B)

Reverse smile arc defines that the incisal edges and the canine cusp tips had a reverse curve relative to the lower lip line. (Fig. 5C)

5. Buccal corridor percentage

A ratio of the distance between the upper dental midline (UM) to the terminal tooth seen (TT) and the distance between the upper dental midline (UM) to the angle of the mouth, or UM-TT/UM-LC

This ratio will be converted to buccal corridor percentage by the formula $(1 - (UM-TT/UM-LC)) \times 100$ (Fig. 4B)

6. Gingival exposure

Vertical distance between the most apical gingival margin of central incisors (UGM) and the lower border of the upper lip (UL)

7. Smile symmetry

The difference between the vertical distance of the interpupillary line to the left angle of the mouth and the vertical distance of the interpupillary line to the right angle of the mouth.

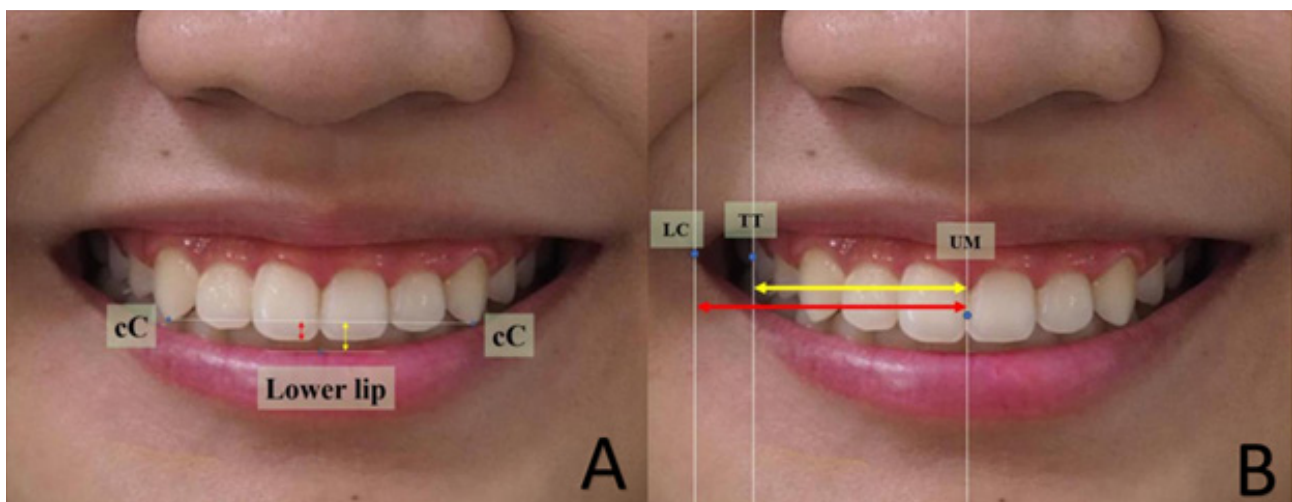


Figure 4 (A) The red line indicates distance from the maxillary incisor edge to the intercanine connecting line. The yellow line represents the distance from the lower lip to the intercanine connecting line. (B) The yellow line indicates the distance from the upper dental midline to the terminal tooth seen (UM-TT). The red line presents the distance from the upper dental midline to the angle of the mouth (UM-LC).



Figure 5 (A) Parallel smile arc (B) Flat smile arc (C) Reverse smile arc

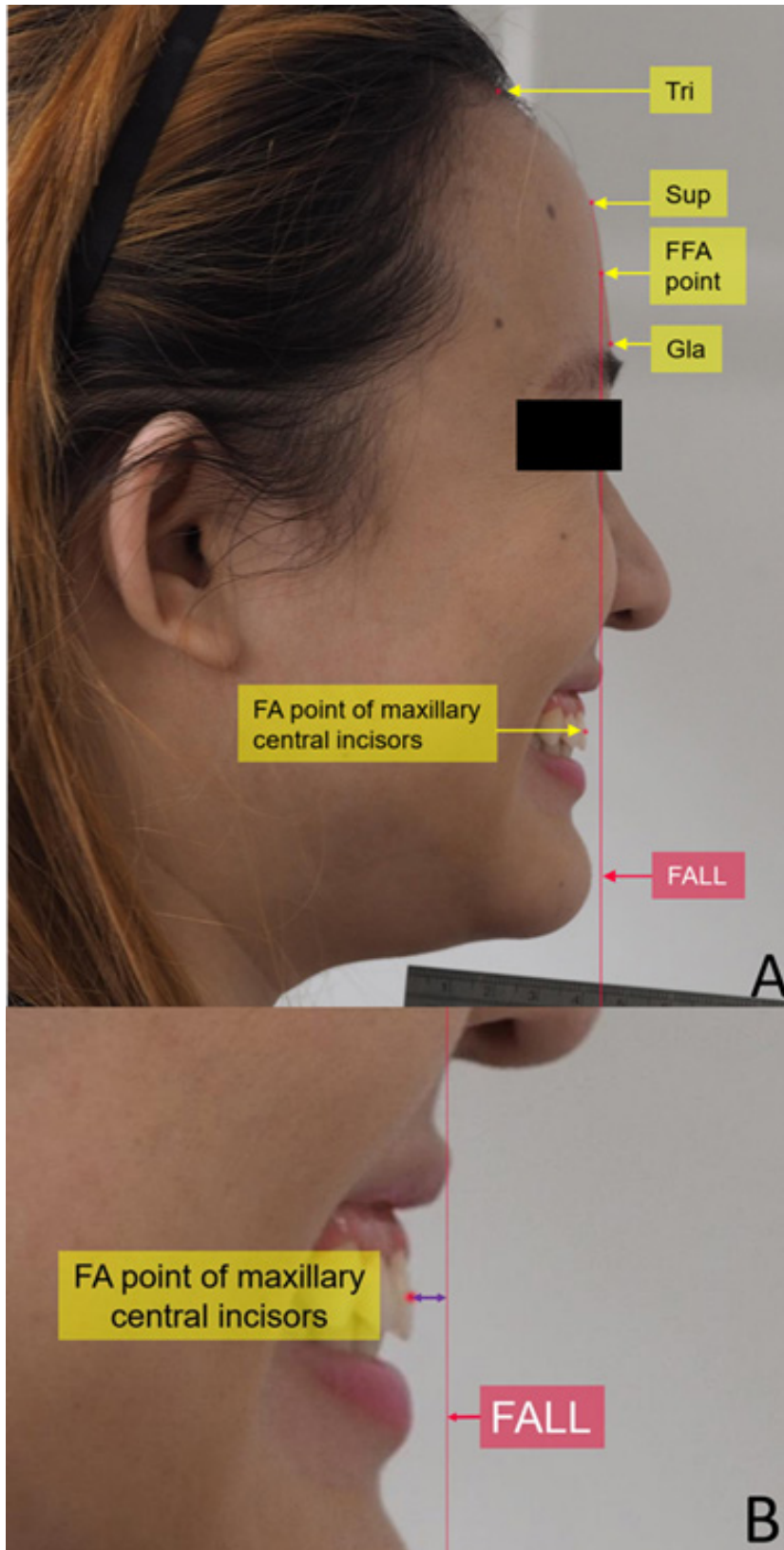


Figure 6 (A) Points and lines plotted in lateral profile picture, (B) Purple line indicates Incisor-FALL

In the lateral position picture, points and lines will be plotted and analyzed as below. (Fig. 6A)

1. Gla (Glabella) is the most anterior projection of the lower forehead.

2. Tri (Trichion) is the junction of the forehead skin and the anterior hairline.

3. Sup (Superion) is the most superior aspect of the forehead.

4. Forehead line is the line drawn from Gla to Tri in a relatively flat forehead shape, and from Gla to Sup in a rounded or an angular forehead shape.

5. FFA point (Forehead's Facial-Axis point) is the midpoint of the forehead line

6. FALL (Forehead anterior limit line) is the vertical line drawn from the FFA point.

7. FA point of the maxillary central incisors is the midpoint on the facial axis between the gingival half and the incisal half of the clinical crown.

8. The horizontal distance from FALL to FA point of the maxillary central incisors is measured and recorded as Incisor-FALL (Fig. 6B)

The frontal smile pictures of all the participants were adjusted to black and white color, the picture presenting only a smile portion. A 10 cm horizontal line was added below each picture as an evaluating scale labeling "least attractive" at the left end and "most attractive" at the right end. The 41 adjusted pictures were shuffled and randomly ordered among the nonextraction and four first extraction groups. Subsequently, three board certified orthodontists and ten laypersons evaluated the smile esthetics by using the VAS score adapted from the study of Gould *et al.*¹¹

The evaluation was done by marking a point in the line to represent the esthetic satisfaction of each smile. After the examiners finished the smile evaluation, the scores were obtained by measuring the distance from

the left end to the marked position. A mean score of the extraction and nonextraction groups were gathered.

Statistical methods

The Statistical Package for Social Science (SPSS) version 26.0 for windows (SPSS Inc., Chicago, IL, USA) was used to calculate the statistics. In part one, the comparisons between the nonextraction group and the four first premolar extraction group were undertaken using an independent *t*-test. The only non-parametric parameter which was smile arc type was undertaken using Pearson's chi-square. In part two, the mean and standard deviation of the VAS scores evaluated by the three board certified orthodontists and ten laypersons in the nonextraction group and the four first premolar extraction group were computed individually. The comparisons between the two groups were undertaken using an independent *t*-test. The results were considered statistically significant at $P < 0.05$.

Results

The nonextraction group comprised 21 participants, including five males and 16 females. The age of the participants within the nonextraction group varied from 15 to 29 years old (mean 21.76 ± 3.83 years old). The mean amount of crowding in the nonextraction group in upper arch and lower arch are 5.35 ± 0.27 mm and 5.58 ± 0.37 mm, respectively. The four first premolar extraction group consist of 20 participants, including six males and 14 females. The age of the participants within the four first premolar extraction group varied from 16 to 28 years old (mean 21.85 ± 3.64 years old). The mean amount of crowding in the four first premolar extraction group in the upper arch and the lower arch are 6.62 ± 1.61 mm and 6.47 ± 1.1 mm, respectively.

The means and standard deviations of smile parameters in the two groups, as well as the comparisons between the two groups are shown in Table 1.

Table 1 The means and standard deviations of smile parameters

Variables	Nonextraction group	Four first premolar extraction group	P value
	Mean ± SD	Mean ± SD	
Right UM-dC/UM-LC	0.60 ± 0.03	0.64 ± 0.03	0.001*
Left UM-dC/UM-LC	0.61 ± 0.03	0.63 ± 0.02	0.046*
RcC-LcC/RAI-LAI	0.78 ± 0.06	0.82 ± 0.03	0.041*
(RAI-LAI) - (RcC-LcC) distance (mm.)	9.38 ± 3.19	7.61 ± 2.03	0.042*
UM-FM (mm.)	0.40 ± 0.44	0.43 ± 0.56	0.851
Sn-UL/Sn-UI	0.62 ± 0.05	0.63 ± 0.07	0.706
Smile arc ratio	0.64 ± 0.25	0.68 ± 0.23	0.616
Right Buccal corridor percentage (1- right (UM-TT/UM-LC)) × 100 (percentage)	18.80 ± 3.53	18.15 ± 3.81	0.578
Left Buccal corridor percentage (1- left (UM-TT/UM-LC)) × 100 (percentage)	18.04 ± 3.45	19.35 ± 3.89	0.263
Gingival exposure (mm.)	0.68 ± 0.96	0.85 ± 1.41	0.647
Smile symmetry (mm.)	0.89 ± 0.59	1.27 ± 0.83	0.100
Incisor-FALL (mm.)	2.00 ± 4.35	0.11 ± 4.70	0.189

*P < 0.05

The mean of the UM-dC/UM-LC ratio of the right and the left in the extraction group was more than the nonextraction group with significant difference. The mean of RcC-LcC/RAI-LAI in the extraction group was significantly more than the nonextraction group. The mean of (RAI-LAI)-(RcC-LcC) distance in the extraction group was significantly less than the nonextraction group. The means of other

parameters were shown non-significantly different between the extraction group and the nonextraction group.

Table 2 shows that the smile arc type difference after orthodontic treatment between the nonextraction and the four first extraction groups was not statistically significant (P = 0.796)

Table 2 Smile arc type after orthodontic treatment of nonextraction and four first premolar extraction groups

	Parallel smile arc (case)	Straight smile arc (case)	Reverse smile arc (case)	Total
Nonextraction group	15	6	0	21
Four first premolar extraction group	15	5	0	20

The mean VAS scores and standard deviation of the nonextraction group and the four first premolar extraction group evaluated by three orthodontists and ten laypersons were shown individually in Table 3. The

scores between the nonextraction group and the four first premolar extraction group were computed statistically and displayed.

Table 3 VAS scores

Participants	VAS of nonextraction group	VAS of four first premolar extraction group	P value
	Mean ± SD	Mean ± SD	
Orthodontist 1	9.17 ± 0.28	9.09 ± 0.21	0.296
Orthodontist 2	9.36 ± 0.28	9.29 ± 0.25	0.079
Orthodontist 3	8.48 ± 0.36	8.30 ± 0.63	0.254
Layperson 1	8.06 ± 0.46	7.96 ± 0.32	0.446
Layperson 2	8.56 ± 1.23	8.16 ± 1.19	0.293
Layperson 3	6.88 ± 1.19	6.35 ± 1.19	0.165
Layperson 4	7.69 ± 1.41	7.02 ± 1.22	0.116
Layperson 5	5.66 ± 0.89	5.29 ± 0.40	0.097
Layperson 6	6.79 ± 1.84	6.27 ± 1.00	0.270
Layperson 7	7.01 ± 1.37	6.93 ± 1.46	0.848
Layperson 8	7.07 ± 1.56	6.57 ± 1.08	0.252
Layperson 9	6.82 ± 1.21	6.22 ± 0.82	0.070
Layperson 10	5.80 ± 1.06	5.53 ± 0.83	0.385

*P < 0.05

The VAS scores rated by each participant presented no statistical difference between the nonextraction group and the four first premolar extraction group.

The interpretation of VAS scores was adapted from a study by Jensen *et al.*¹¹ The modified categorization of VAS scores is as follows: 0-0.4 indicating no satisfaction, 0.5-4.4 indicating mild satisfaction, 4.5-7.4 indicating moderate satisfaction, and 7.5-10 indicating high satisfaction.

All of the orthodontists and the two laypersons rated VAS scores of both the non-extraction group and the four first premolar extraction group as highly satisfying, with a mean VAS of 7.96 ± 0.32 to 9.36 ± 0.28.

One layperson rated the VAS scores of the non-extraction group as highly satisfying (with a mean of 7.69 ± 1.41) and the four first premolar extraction group as moderately satisfying (with a mean of 7.02 ± 1.22). However, there was no significant difference.

Seven laypersons rated VAS scores of both the non-extraction group and the four first premolar extraction group as moderately satisfying, with a mean VAS of 5.29 ± 0.40 to 7.07 ± 1.56.

Discussion

This study focuses on the comparison of the maxillary anterior teeth positioning and the smile appearance between a nonextraction orthodontically treated group and a group treated with orthodontic extraction of four first premolars in Cl I moderate crowding. The objective is to evaluate maxillary anterior teeth positioning and smile appearance after orthodontic treatment.

According to Peck *et al.*¹² there are two stages of a smile. The muscles that originate in the nasolabial groove pull the lip upward in the first stage until they run into opposition from the adipose tissue in the cheeks. The additional muscle groups are recruited in the second stage. To achieve the highest elevation of the upper lip toward the nasolabial angle, the muscles around the periorbital area must contract, resulting in eye squinting. To obtain genuine smiles in this study, participants were instructed to smile with a “maximum smile and squinting eyes”.

The position of the canines was suggested to be at the parallel line vertically drawn from the lateral surface of the alar of the nose.¹³ However, Maskey *et al.*¹⁴

found that the mean of the intercanine width were greater than the mean of the interalar width when measuring the interalar width while participants were in the rest position. In order to smile, the levator labii superioris alaeque nasi muscles elevate and dilate a nostril.¹⁵ Therefore, the size of the alar is normally bigger when smiling than in the resting position. This study analyzed the interalar width while participants were smiling and showed that the mean ratio of intercanine to interalar width was found to be greater in the four first premolar extraction group than in the nonextraction group with significant differences. Thus, retracting the canines distally in participants undergoing first premolar extraction may reduce the distance between the canines and the lateral surface of the alars. Interestingly, both groups had their canine cusp tips mesial to the alar of the nose after orthodontic treatment.

In consideration of the canine positions and the labial commissure, several previous studies indicated no significant differences between extraction and nonextraction participants when comparing the ratio of maxillary intercanine width to inter commissure width.^{6,16} On the other hand, this study revealed that the extraction group's mean ratios were significantly higher on both the left and right sides than the nonextraction group. It is possible that the retracting canine distally in the four first premolar extraction group brought the canine closer to the lip commissure than in the nonextraction group, resulting in a higher ratio of upper dental midline and distal surface of the maxillary canine to the upper dental midline and angle of the mouth than in the nonextraction group.

According to previous studies,¹⁷⁻¹⁹ the mean maxillary intercanine width after posttreatment of the four first premolar extracted patients tended to be greater than the pretreatment intercanine width. The assumption is that, in the premolar extraction group, canines have to be retracted distally and occupy some of the spaces previously occupied by premolars, consequently increasing maxillary intercanine width. When the maxillary canines are retracted distally in the premolar extracted cases, the mandibular canines also have to be retracted distally as well to achieve

canine Class I. Retracting maxillary and mandibular canines distally too far might result in an excessive increase in the maxillary and mandibular intercanine width. The mandibular intercanine width was suggested to be almost the same before and after treatment, since altering the width might result in unstable outcome.²⁰ It is also assumed that the retracting canine too distally might create a lot of space for incisors contraction which might result in upright or retroclined incisors after the treatment.

There was an agreement that orthodontists exhibited a higher sensitivity to midline discrepancies compared to laypersons. On average, orthodontists could identify midline deviations exceeding 2.2 mm, whereas laypersons were only able to perceive midline deviations greater than 3 mm.²¹ In this study, the mean upper midline deviation to the facial midline in the nonextraction group and the four first premolar extraction group were 0.40 mm. and 0.43 mm respectively. The mean difference between the two groups also did not differ significantly. The findings of this study demonstrated that both the nonextraction and the four first premolar extraction treatments might result in acceptable dental midline deviation.

The inclination of the upper incisors in four first premolar extraction orthodontic treatment was found to be more retrocline during the treatment.²² Consequently, the upright or the retroclined maxillary incisors might result in excessive incisal shown.²³ The upper lip length was also reported to slightly increase after premolar extraction because upper lip lost support from the retroclined upper central incisors, allowing the upper lip to be in a lower position.²⁴ Therefore, the ratio of the distance between the subnasale (Sn) to the lower border of the upper lip (UL) and Sn to the incisal edge of the maxillary central incisors (UI) might not differ in the nonextraction and the premolar extraction groups. Consistent with this assumption, this study found that the mean Sn-UL/Sn-UI in the nonextraction and the four first premolar extraction groups did not differ significantly.

To define the suitable position of maxillary central incisors while smiling in the lateral position, Andrews LF25

invented a method using the forehead of a patient as a landmark. This method was later accepted and widely used in several studies to define the maxillary central incisors position in a lateral profile picture while smiling.^{26,27} In this study, the mean FA-FALL distances in the non-extraction group and the four first premolar extraction were 2.00 ± 4.35 mm and 0.11 ± 4.70 mm respectively. Retracting maxillary canines and incisors in the four first premolar extraction group tended to move maxillary central incisors palatally and affected FA-FALL to be less positive or more minus than the nonextraction group. However, the mean FA-FALL of the two groups did not differ significantly. There were some methods that prevent excessive maxillary retroclined incisors which might control the FA-FALL of the extraction group such as increasing torque in the anterior teeth by putting a third order bend in main archwire or using a full-dimension archwire to express the build-in torque in the brackets.^{28,29}

Smile arc in nonextraction orthodontic treatment patients was predicted to flatten due to incisor proclination.^{4,7} However, this study found no significant difference in smile arc type and ratio after orthodontic treatment between the nonextraction and the extraction patients. Extraction or nonextraction is not the only factor that impacts smile arc since there are several other factors which affect the smile arc such as maxillary incisors over intrusion, poor bracket positioning, and canted anteriorly maxillary occlusal plane.²³

The current study used the same method as Maulika and Nanda's study to calculate the buccal corridor percentage.⁸ The results indicated a minor difference in the percentages of buccal corridors between the extraction and the non-extraction groups with no significant difference. Similarly, Ghaffar *et al.*⁶ revealed that there was no significant difference in the buccal corridor between the extraction and the nonextraction groups when the buccal corridor was compared. Meyer *et al.*¹⁹ also discovered that the mean difference in buccal corridor percentages between the extraction and the nonextraction groups was only 1%.

The amount of gingival exposure is one of several factors affecting smile esthetics.³⁰ Sharma and Sharma¹ suggested that showing 1-2 mm of gingiva while smiling was the most attractive smile. Fallas *et al.*²⁴ reported that both upper first premolar and second premolar extraction orthodontic treatments might result in a more vertical gingival display in the maxillary upper incisal region because retracting anterior teeth palatally could extrude those anterior teeth as well. Consequently, the extruded teeth brought the gingival and alveolus bone together with the teeth which result in increased gingival display. However, Ghaffar and Fida⁶ found that the number of patients with gingival exposure among both groups were not significantly different. This study found that the mean gingival display of the four first premolar extraction group was slightly higher than the nonextraction group; nevertheless, there was no significant difference between the mean gingival display of the two groups. Although extraction treatment might affect incisor extrusion, there are some methods that can control incisor extrusion while retraction such as using low force during space closure to prevent canine distal tipping which leads to bite deepening, and avoiding canine retraction on a round wire.³¹ Apart from these, the upper incisors could also be intruded in the finishing stage to correct excessive overbite.²⁸

Benson and Laskin³² examined the incidence of smile asymmetry in normal participants and found that 8.7% were diagnosed with an asymmetrical smile. In this study, the smile symmetry was evaluated by the difference between the left and the right corners of the mouth to the interpupillary line which was recommended by several articles.^{23,33} The mean difference of smile symmetry among the nonextraction group and the four first premolar extraction group in this study did not differ significantly. To our knowledge, no data comparing smile asymmetry between the nonextraction and the four first premolar extraction orthodontic treatments exist.

The Visual Analog Scale (VAS) was proved to offer good validity and reliability in determining dental and facial

attractiveness.³⁴ Several studies^{9,10,35} used the VAS score to obtain smile esthetic scores from participants. To diminish confounding factors in the pictures of this study, only part of mouth and teeth were cropped and shown to the judges. Showing the entire face might distract attention from the smile part because raters might focus on other parts of the face as well.³⁵ The difference in tooth color shade could also affect smile esthetic.^{1,30} To reduce the bias, the color of the pictures was also adjusted to be black and white.

In the perspective of smile esthetic comparisons between extraction and nonextraction orthodontic treatments, several studies^{16,18} found no significant difference in smile esthetic outcomes between the extraction and the nonextraction groups. In this study, thirteen judges including three board certified orthodontists and ten laypersons were recruited to rate the smile esthetic of the nonextraction and the four first premolar extraction after orthodontic treatment. None of the judges gave significantly different esthetic scores between the two treated groups.

This study found that the VAS scores given by the three orthodontists are closely grouped, while the VAS scores provided by laypersons tend to be more widely spread. Althagafi³⁶ discovered that the individuals in the higher education group exhibited a greater perception of the ideal smile, with fifth-year dental students having a higher perception of an attractive smile than fourth-year dental students. It is assumed that the orthodontic group is more likely to rate VAS scores based on their professional knowledge, leading to a convergence of scores. Laypersons, on the other hand, might assign VAS scores based on their subjective feelings, resulting in greater variation among their scores. Even though the VAS scores between the participants are different, every participant showed no statistical difference in VAS scores between the non-extraction group and the four first premolar extraction group when comparing between themselves. This implies that despite differences in the participants' esthetic perceptions, the participants in this study still considered

the esthetics of both the nonextraction group and the four first premolar extraction group to be similar.

This study found that the canine positions in the four first premolar extraction group were closer to the alar of the nose and the labial commissure than those in the nonextraction group. However, the positions of the canine cusp tips in all the participants were found to be mesial to the alar of the nose in both groups. The findings of this study could be beneficial in clinical application particularly in the four first premolar extraction cases to determine the positions of canines. From the results of this study, it is believed that the cusp tips of canines should not be positioned distally to the alar of the nose when measured in the frontal smiling position.

The mean difference of VAS scores and several smile parameters between the nonextraction group and four first premolar extraction group in this study did not differ significantly. With respect to the results of this study, the belief that extraction orthodontic treatment impairs smile esthetics is unlikely to be true. In order to make a decision whether to adopt nonextraction or extraction orthodontic treatment, several factors such as skeletal relationship, initial inclination and position of incisors, overjet, and overbite should be carefully considered.

This study measured smile parameters from 2D pictures in the frontal and the lateral positions. For future studies, three-dimensional face models could help access smile parameters in different angles. Moreover, the participants recruited in this study were diagnosed with only Class I malocclusion. The smile parameters after finishing orthodontic treatment of participants with Class II or Class III malocclusion should be focused on in future studies.

Conclusions

1. The maxillary canines of the four first premolar extraction group are closer to the alar of the nose and the labial commissures than the nonextraction group.
2. There are no significant differences between the upper dental midline, the upper lip length and the

upper dental display, the FA of the maxillary central incisors to FALL, buccal corridor percentage, smile arc, gingival exposure, and smile symmetry of the nonextraction and the four first premolar extraction orthodontically treated participants.

3. In the judgments of orthodontists and laypersons, there are no significant differences in the smile esthetics measured by the visual analog scale (VAS) in frontal smiling pictures after orthodontic treatment between the nonextraction participants and the four first premolar extraction participants.

References

- Sharma P, Sharma P. Dental smile esthetics: the assessment and creation of the ideal smile. *Semin Orthod* 2012;18:193–201.
- Premkumar S. Space gaining procedures. Textbook of orthodontics. First ed: Elsevier; 2015. p. 656-75.
- Dierkes JM. The beauty of the face: an orthodontic perspective. *J Am Dent Assoc* 1987;115:89e-95e.
- Umrani S, Mathew P, Hemant A, Tiwari R, Dixit H. A review on Extraction versus Non-extraction on Facial and Smile Esthetics. *J Int Dent Medical Res* 2018;4(3):83-6.
- Proffit WR, Fields HW, Larson BE, Sarver DM. Orthodontic treatment planning: from problem list to specific plan. Contemporary orthodontics. Sixth ed. Philadelphia: Elsevier; 2019. p. 208-46.
- Ghaffar F, Fida M. Effect of extraction of first four premolars on smile aesthetics. *Eur J Orthod* 2011;33(6):679-83.
- Cheng HC, Wang YC. Effect of nonextraction and extraction orthodontic treatments on smile esthetics for different malocclusions. *Am J Orthod Dentofacial Orthop* 2018;153(1):81-6.
- Maulik C, Nanda R. Dynamic smile analysis in young adults. *Am J Orthod Dentofacial Orthop* 2007;132(3):307-15.
- Ritter DE, Gandini LG, Pinto Ados S, Locks A. Esthetic influence of negative space in the buccal corridor during smiling. *Angle Orthod* 2006;76(2):198-203.
- Sriphadungporn C, Chamnanniadha N. Perception of smile esthetics by laypeople of different ages. *Prog Orthod* 2017;18(1):1-8.
- Gould D, Kelly D, Goldstone L, Gammon J. Examining the validity of pressure ulcer risk assessment scales: developing and using illustrated patient simulations to collect the data. *J Clin Nurs* 2001;10(5):697-706.
- Peck S, Peck L. Selected aspects of the art and science of facial esthetics. *Semin Orthod* 1995;1(2):105-26.
- Wehner PJ, Hickey JC, Boucher CO. Selection of artificial teeth. *J Prosthet Dent* 1967;18(3):222-32.
- Maskey S, Shrestha R, Yadav R, Yadav N. Relation between Inter alar width and inter canine distance in aid for the replacement of artificial maxillary anterior teeth. *J Med Sci Clin Res* 2018;6:624-8.
- Hur MS, Hu KS, Park J, Young K, Kim H. New anatomical insight of the levator labii superioris alaeque nasi and the transverse part of the nasalis. *Surg Radiol Anat* 2010;32(8):753-6.
- Prasad V, Tandon P, Singh G, Nagar A, Maurya RP. Comparison of smile esthetics after extraction and non-extraction orthodontic treatment. *Indian J Orthod Dentofacial Res* 2019;4:182-9.
- Işık F, Sayınsu K, Nalbantçıl D, Arun T. A comparative study of dental arch widths: extraction and non-extraction treatment. *Eur J Orthod* 2005;27(6):585-9.
- Kim E, Gianelly AA. Extraction vs nonextraction: arch widths and smile esthetics. *Angle Orthod* 2003;73(4):354-8.
- Meyer AH, Woods MG, Manton DJ. Maxillary arch width and buccal corridor changes with orthodontic treatment. Part 1: differences between premolar extraction and nonextraction treatment outcomes. *Am J Orthod Dentofacial Orthop* 2014;145(2):207-16.
- Uribe FA, Chandhoke TK, Nanda R. Individualized orthodontic treatment planning. Esthetics and biomechanics in orthodontics: Elsevier; 2005. p. 33-53.
- Janson G, Branco NC, Fernandes TM, Sathler R, Garib D, Lauris JR. Influence of orthodontic treatment, midline position, buccal corridor and smile arc on smile attractiveness. *Angle Orthod* 2011;81(1):153-61.
- Celikoglu M, Kamak H, Akkas I, Oktay H. Effects of orthodontic treatment and premolar extractions on the mandibular third molars. *Aust Orthod J* 2010;26(2):160-4.
- Sabri R. The eight components of a balanced smile. *J Clin Orthod* 2005;39:155-67.
- Fallas MF, Abu-Alhajja ES, Alkhateeb SN, Samawi SS. Vertical gingival display changes associated with upper premolars extraction orthodontic treatment: A prospective clinical trial. *J Clin Exp Dent* 2020;12(11):e1050-7.
- Andrews LF. The six elements of orofacial harmony. *Andrews J Orthod Orofac Harmony* 2000;1:13-22.
- Andrews WA. AP relationship of the maxillary central incisors to the forehead in adult white females. *Angle Orthod* 2008;78(4):662-9.
- Schlosser JB, Preston CB, Lampasso JJ. The effects of computer-aided anteroposterior maxillary incisor movement on ratings of facial attractiveness. *Am J Orthod Dentofacial Orthop* 2005;127(1):17-24.
- Proffit WR, Fields HW, Larson BE, Sarver DM. Comprehensive treatment: finishing. Contemporary orthodontics. Sixth ed. Philadelphia: Elsevier; 2019. p. 556-78.
- McLaughlin RP, Bennett JC. Finishing with the preadjusted orthodontic appliance. *Semin Orthod* 2003;9(3):165-83.
- Machado AW. 10 commandments of smile esthetics. *Dental Press J Orthod* 2014;19(4):136-57.
- McLaughlin RP, Bennett JC. Evolution of treatment mechanics and contemporary appliance design in orthodontics: A 40-year perspective. *Am J Orthod Dentofacial Orthop* 2015;147(6):654-62.

32. Benson KJ, Laskin DM. Upper lip asymmetry in adults during smiling. *J Oral Maxillofac Surg* 2001;59(4):396-8.
33. Manjula W, Sukumar M, Kishorekumar S, Gnanashanmugam K, Mahalakshmi K. Smile: A review. *J Pharm Bioallied Sci* 2015;7 (Suppl 1):S271-5.
34. Howells DJ, Shaw WC. The validity and reliability of ratings of dental and facial attractiveness for epidemiologic use. *Am J Orthod* 1985;88(5):402-8.
35. Pinzan-Vercelino CRM, Costa ACS, Ferreira MC, Bramante FS, Fialho MPN, de Araújo Gurgel J. Comparison of gingival display in smile attractiveness among restorative dentists, orthodontists, prosthodontists, periodontists, and laypeople. *J Prosthet Dent* 2020;123(2):314-21.
36. Althagafi N. Esthetic Smile Perception Among Dental Students at Different Educational Levels. *Clin Cosmet Investig Dent* 2021; 13:163-72.