

The Outcome of Two-jaw Orthognathic Surgery Using 3-Dimensional Analysis of Virtual Surgical Planning: A Retrospective Study

Sappasith Panya¹, Wichuda Kongsong¹, Keskanya Subbalekha¹

¹Department of Oral and Maxillofacial Surgery, Faculty of Dentistry, Chulalongkorn University, Bangkok, Thailand

Abstract

The purpose of this study was to evaluate outcomes of three-dimensional analysis of virtual surgical planning for two-jaw orthognathic surgery. A retrospective study of 13 patients (four males, nine females) was conducted. Cone beam computed tomography images were imported into a Dolphin program, virtual surgical planning was performed and used to fabricate surgical splints. Postoperatively, the planned and actual position were generated as a three-dimensional skeletal model using a Dolphin program. Then, ten bone positions were created and 30 values were measured to compare the predicted outcomes and actual outcomes at six months after surgery. The mean age of the 13 patients was 29 years old. The mean difference of the total of the ten bone positions in the antero-posterior direction was 1.76 ± 2.83 mm, in the vertical direction was 2.12 ± 1.47 mm, and in the medio-lateral direction was 0.91 ± 0.76 mm. There was a significant difference between the antero-posterior position at the A-point ($P = 0.006$) and the planned position. In conclusion, the utilization of virtual surgical planning by the Dolphin program was a reliable method for two-jaw orthognathic surgery, and the antero-posterior position at the A-point of the maxilla was still a sensible position.

Keywords: Computer aided surgical simulation, Orthognathic surgery, Virtual surgery, Virtual surgical planning

Received Date: Jun 8, 2021

Revised Date: Jul 26, 2021

Accepted Date: Aug 25, 2021

doi: 10.14456/jdat.2022.31

Correspondence to:

Keskanya Subbalekha, Department of Oral and Maxillofacial Surgery, Faculty of Dentistry, Chulalongkorn University 34 Henri Dunant Road, Wang Mai, Patumwan, Bangkok, 10330, Thailand. Tel: 02-218-8592 Fax: 02-218-8581 E-mail: skeskanya@gmail.com

Introduction

Two-jaw orthognathic surgery is an efficient procedure to correct skeletal and occlusal discrepancies. The success of orthognathic surgery relies not only on trained surgical techniques but also on accurate surgical planning. Conventional treatment planning requires multiple analyses,

including a clinical evaluation, 2-dimensional (2D) cephalometric radiography, face-bow transfer and trial surgery on plaster dental models. Then, intermediate and final occlusal splints are fabricated and utilized to guide the position of the maxilla and mandible according to the plan. Although the

conventional process has provided satisfactory results, there are certain limitations such the process being time-consuming and complicated with some inaccuracies.^{1,2}

Currently, three-dimensional (3D) virtual surgical planning (VSP) has been developed and used as a new tool to obtain a comprehensive 3D evaluation of the dentofacial structures, simulate different surgical plans and predict the corresponding results. Moreover, VSP is transferred to actual surgery by using 3D printed splints and guiding templates. Therefore, the utilization of VSP offers more information on the anatomy of the patient during planning, better communication between the surgeon and the orthodontist, a reduction in the operating time and improvement in accuracy.^{2,6} Numerous reports regarding VSP in orthognathic surgery have been published, and most of them investigated feasibility or emphasized the potential benefits of VSP over conventional techniques.^{2,6-8} Recent systematic review and meta-analysis has advocated the use of VSP as an alternative method for the conventional technique for orthognathic surgery, especially for two-jaw surgery.⁶

Several studies have compared the accuracy of VSP in two-jaw orthognathic surgery before and within six weeks after surgery.⁸⁻¹¹ A longer period study, i.e., three or six months postoperatively, of an actual bone position was naturally not only referred to accuracy but also to the stability of the surgery. However, investigation on treatment outcomes of 3D VSP in two-jaw orthognathic surgery for a longer period has been limited.^{12,13} Therefore, the objective of this retrospective study was to assess treatment outcomes of VSP using a Dolphin program by comparing a predicted outcome to an actual outcome (six-month postoperatively).

Materials and Methods

This retrospective cohort study was approved by the Ethics Committee of the Faculty of Dentistry, Chulalongkorn University (HREC-DCU 2020-017). Seventeen patients, who underwent two-jaw orthognathic surgery by one experienced oral and maxillofacial surgeon (S.S.) at the Dental Hospital of the Faculty of Dentistry, Chula-

longkorn University, were initially recruited. Thirteen patients were selected based on the inclusion criteria, including non-growing patients, availability of good quality pre- and postoperative cone beam computed tomography (CBCT), surgical treatment planning using VSP and surgical splints fabricated by 3D printing technology. Patients with craniofacial anomalies, syndromes, history of trauma, previous orthognathic surgery, simultaneous additional surgical procedures, or poor-quality medical record were excluded.

The patients underwent a preoperative CBCT (slice thickness 1 mm) and dental arch scanning two weeks before surgery. DICOM (Digital Imaging and Communications in Medicine) data of the CBCT scans and stereolithography (STL) data from dental arch scanning were imported into a Dolphin program (version 11.95, Patterson Dental Supply Inc., US) for analysis. After VSP was done, the data of the final designed surgical splints were exported as an STL file to a 3D printer, and then the individual surgical splints were fabricated.

All patients underwent a standard two-jaw orthognathic surgery under general anesthesia. A Le Fort I osteotomy was performed on the maxilla. An intermediate splint was used to guide the planned position of the maxilla. After the maxilla had been fixated with 1.5-mm titanium plates and screws, a bilateral sagittal split ramus osteotomy (BSSRO) procedure was performed on the mandible. A final splint was used to achieve the planned occlusion, then the mandible was fixated with 2-mm titanium plates and screws. Patients were placed in maxillomandibular fixation for two weeks postoperatively.

Six months after surgery, the same protocol of postoperative CBCT scan was performed. Preoperative 3D virtual planning data of each patient was compared with postoperative actual positions of the maxilla and mandible. Demographic data including age, gender, diagnosis, and complications were recorded. All data were collected by one researcher (S.P.).

To assess the accuracy of VSP, differences of final outcomes at six-month postoperatively and surgical planning were determined. The reference planes were the

Frankfort Horizontal Plane (FHP), the midfacial plane (a vertical plane passing through the nasion and perpendicular to the FHP), and the coronal plane (a vertical plane passing through the sella point and perpendicular to the FHP). These reference planes were used for orientation and measurement in each axis. Ten bone reference points were modified from previous studies^{14,15} and created at the maxilla (Fig. 1) and the mandible (Fig. 2) for 3D analysis:

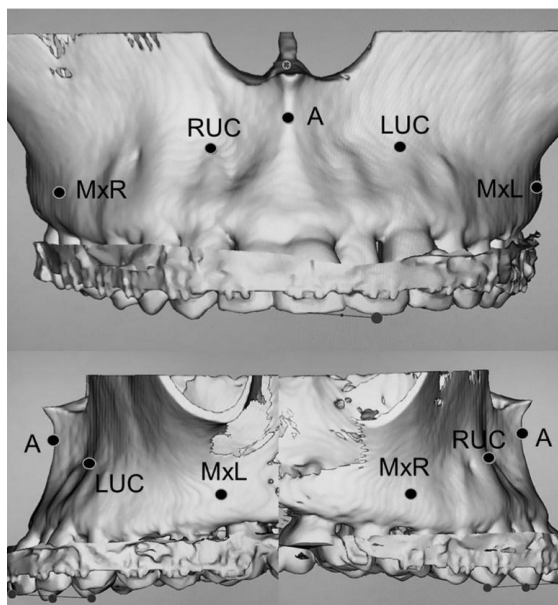


Figure 1 The reference points of the maxilla. A, A-point; RUC, Right upper canine root tip; LUC, Left upper canine root tip; MxR, Right maxillary point; MxL, Left maxillary point

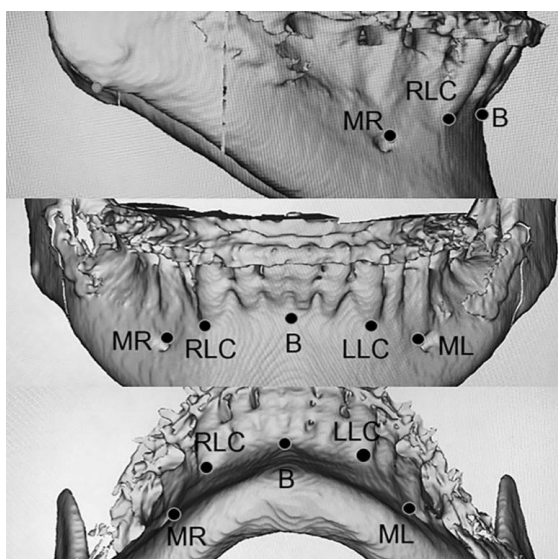


Figure 2 The reference points of the mandible. B, B-point; RLC, Right lower canine root tip; LLC, Left lower canine root tip; MR, Right mandibular point; ML, Left mandibular point

- MAXILLA: A, A-point (most posterior midline point in the concavity of the alveolar bone of the maxilla); RUC, Right upper canine root tip (root apex of the right upper canine); LUC, Left upper canine root tip (root apex of the left upper canine); MxR, Right maxillary point (most convex point on the alveolar bone of the right upper molar); MxL, Left maxillary point (most convex point on the alveolar bone of the left upper molar).

- MANDIBLE: B, B-point (most posterior midline point in the concavity of the alveolar bone of the mandible); RLC, Right lower canine root tip (root apex of the right lower canine); LLC, Left lower canine root tip (root apex of the left lower canine); MR, Right mandibular point (antero-superior point of the right mental foramen); ML, Left mandibular point (antero-superior point of the left mental foramen).

The differences were evaluated by the difference of the distance from the reference points to the reference plane on the preoperative 3D virtual planning and postoperative skeletal 3D model by using the Dolphin program. With ten reference points multiplied by three different axes (X, antero-posterior; Y, vertical; Z, medio-lateral), 30 values were measured pre- and postoperatively for each patient. These references provided sufficient detail about the difference in each direction of the jaw position.

Sample size calculation was performed by a G-power program. Two dependent means comparison with matched paired *t*-test was selectively coordinated with the mean and standard deviation (SD) value of the previous study.¹⁴ The calculated total sample size was five with more than 0.95 power. To determine the reliability of the measurements, a sample of four patients was randomly selected and their images were analyzed again after a two-month interval. The Intra-class Correlation Coefficients (ICC) were computed to assess the intra-observer reliability for the measurements. An ICC score of 0.75 or higher was considered as an acceptable reliability for our quality control criterion. The ICCs of this study were > 0.9 for all measurements, indicating high consistency and reproducibility.

Statistical analysis was performed by using SPSS version 22.0 (SPSS Inc., Chicago, IL, USA). Results were

expressed descriptively as mean values, including standard deviation of the mean and range. Means of difference in planned and actual outcomes were compared by the paired *t*-test. In addition, subgroup analysis was analyzed using the independent *t*-test. A *P* value of <0.05 was considered significant. Correlation and regression analysis were performed depending on the results.

Results

Demographic data

Thirteen patients met the inclusion criteria for participants, of which four were male and nine were female with a mean age of 29 years old (ranging from 20 to 54 years old). All the patients were diagnosed with “facial asymmetry”. There were no eventful complications during and postoperative surgery in all the patients. Overall clinical outcomes were satisfied.

Treatment Outcome

The majority of the operation aimed to correct canting of the maxilla (11 of 13 patients). Nine of the 13 patients underwent correction of the antero-posterior

position of the maxilla. The mean surgical change of the maxillary position was 3.07 mm in the vertical direction, 1.76 mm in the antero-posterior direction, and 0.31 mm in the medio-lateral direction.

In general, the mean difference of a total of ten bone positions in the antero-posterior direction was 1.76 ± 2.83 mm, the vertical direction was 2.12 ± 1.47 mm, and the medio-lateral direction was 0.91 ± 0.76 mm. Separately, the mean difference of the maxillary bone positions was lower than of the mandibular bone positions. To be precise, the exact value was antero-posterior: vertical: mediolateral = 1.35: 1.86: 0.85 mm in the maxilla and 2.16: 2.37: 0.91 mm in the mandible.

Postoperatively, there was a significant difference of antero-posterior position at the A-point (*P* = 0.006) compared with the planned position. The mean difference of the antero-posterior position at the A-point was 1.56 ± 1.7 mm. The mean differences of the planned and actual positions of the maxilla and the mandible are shown in Tables 1 and 2, respectively.

Table 1 The differences of the planned and the actual positions of the maxilla

Variable-Axis	Planned (mm) (mean \pm SD)	Actual (mm) (mean \pm SD)	Difference (mm) (mean \pm SD)	<i>P</i> -value
A-X	42.2 \pm 2.9	40.64 \pm 3.1	1.56 \pm 1.7	0.006*
A-Y	26.73 \pm 4.5	26.32 \pm 5.7	0.41 \pm 2.4	0.55
A-Z	0.9 \pm 0.4	0.86 \pm 0.7	0.03 \pm 0.7	0.86
RUC-X	35.27 \pm 3.3	35.01 \pm 2.9	0.25 \pm 1.6	0.59
RUC-Y	24.82 \pm 4	24.87 \pm 5.4	0.04 \pm 2.6	0.95
RUC-Z	16.04 \pm 2	15.76 \pm 1.9	0.28 \pm 0.8	0.26
LUC-X	34.4 \pm 3.2	34.06 \pm 2.9	0.34 \pm 2	0.56
LUC-Y	25.71 \pm 4.7	25.43 \pm 5.9	0.28 \pm 2.4	0.68
LUC-Z	15.79 \pm 1.9	15.55 \pm 1.8	0.2 \pm 1.4	0.62
MxR-X	21.98 \pm 6	21.57 \pm 5.7	0.4 \pm 1.7	0.42
MxR-Y	33.07 \pm 5.3	32.64 \pm 5.5	0.42 \pm 2.2	0.51
MxR-Z	28.73 \pm 1.8	29.08 \pm 1.3	0.34 \pm 1.4	0.41
MxL-X	20.96 \pm 5.3	20.81 \pm 5.3	0.14 \pm 1.8	0.78
MxL-Y	34.38 \pm 6.1	33.35 \pm 6.1	1.01 \pm 2.5	0.18
MxL-Z	28.33 \pm 1.8	28.23 \pm 2.3	0.1 \pm 0.9	0.71

Paired *t*-test. * Significant at *P* < .05.

Table 2 The differences of the planned and the actual positions of the mandible

Variable-Axis	Planned (mm) (mean ± SD)	Actual (mm) (mean ± SD)	Difference (mm) (mean ± SD)	P-value
B-X	39.6 ± 6.4	39.06 ± 6.2	0.53 ± 2.6	0.48
B-Y	65.2 ± 5.6	64.09 ± 5	1.1 ± 2.8	0.18
B-Z	1.06 ± 1.4	1.07 ± 1.1	0.01 ± 1.1	0.96
RLC-X	34.89 ± 6.1	34.47 ± 5.6	0.41 ± 2.7	0.59
RLC-Y	64.52 ± 4.3	64.14 ± 5.4	0.37 ± 2.4	0.59
RLC-Z	14.73 ± 1.3	14.29 ± 1.9	0.44 ± 1.5	0.32
LLC-X	34.58 ± 5.9	34.6 ± 5.4	0.01 ± 2.9	0.99
LLC-Y	65.11 ± 5.3	64.24 ± 6.3	0.87 ± 2.5	0.24
LLC-Z	14.57 ± 2.1	14.47 ± 2.1	0.10 ± 1.1	0.77
RM-X	27.17 ± 6.4	26.79 ± 4.7	0.38 ± 2.6	0.61
RM-Y	67.89 ± 4.5	67.12 ± 5.4	0.76 ± 3.2	0.41
RM-Z	22.6 ± 2.3	22.05 ± 2.8	0.55 ± 1.2	0.13
LM-X	25.31 ± 6.3	25.31 ± 5.7	0.001 ± 3.2	1
LM-Y	69.14 ± 5.9	68.27 ± 5.9	0.87 ± 2.3	0.21
LM-Z	23.26 ± 2.8	23.64 ± 2.9	0.38 ± 1.3	0.31

Paired t-test.

Subgroup analysis

According to the results, there was a significant difference at the A-point and all the patients of the present study had facial asymmetry so that maxillary canting correction was needed. To find if the degree of the antero-posterior or the vertical movement of the maxilla affected the post-operative jaw position, the patients were divided into two groups. The mean surgical change in the antero-posterior direction was 1.76 mm and the vertical direction was 3.07 mm,

therefore, 2 and 4 mm were used as cut-off values to divide the patients for comparison of the mean difference in the antero-posterior and the vertical directions, respectively. While the difference in the antero-posterior position of the maxilla was compared, there was no significant difference between the two groups (Table 3). Also, no significant differences were found on the vertical position of the posterior maxilla between the groups (Table 4).

Table 3 Subgroup analysis of the difference in the antero-posterior (AP) position of the maxilla

	n	Mean of difference (mm)	SD
AP change > 2 mm	3	2.49	1.97
AP change ≤ 2 mm	10	1.56	1.33
		P-value	0.35

Independent t-test.

Table 4 Subgroup analysis of the difference in the vertical position of the posterior maxilla

	Vertical change	n	Mean of difference (mm)	SD	P-value
Right posterior maxilla	≥ 4 mm	5	1.37	1.77	0.44
	< 4 mm	8	2.03	1.23	
Left posterior maxilla	≥ 4 mm	5	2.77	2.64	0.25
	< 4 mm	8	1.5	1.17	

Independent t-test.

Correlation of the difference in the antero-posterior position at A-point and movement of the maxilla

The difference in the antero-posterior position at the A-point of the maxilla was the only significant value of the planned and actual postoperative outcomes. Spearman's

correlation was used to analyze the relationship between this difference and the maxillary movement of each direction (antero-posterior, vertical, and medio-lateral direction). However, this correlation was not significant (Table 5). Therefore, no further regression analysis was performed.

Table 5 Correlation of the difference in the antero-posterior position at the A-point (A) and the maxillary movement of each direction

Difference	Spearman's correlation	Maxillary movement (mm)		
		Antero-posterior	Vertical	Medio-lateral
A-X	r_s	0.27	-0.24	0.06
	P value	0.37	0.41	0.84
A-Y	r_s	-0.13	-0.04	0.34
	P value	0.66	0.9	0.25
A-Z	r_s	0.25	0.08	-0.30
	P value	0.4	0.78	0.31

Discussion

This study evaluated the outcome of two-jaw surgery that used 3D VSP for surgical planning and surgical splint fabrication. The position of the maxilla and mandible were compared between the planned and the six-month postoperative actual values. Ten references to the bone anatomy in three dimensions were used, therefore 30 values were compared. There were no significant differences in any of the values except the antero-posterior position of the maxillary A-point. Kim *et al.*¹⁴ reported approximately 1.01 ± 0.3 mm error at both the A-point and the anterior nasal spine (ANS) from the 3D study which was lower than in the present study (1.56 ± 1.7 mm at A-point). This inferred sensible intraoperative positioning of the anterior maxilla. Kim *et al.*¹⁴ suggested that the A-point and the ANS, including the posterior nasal spine, are always the site of bone removal during the surgical procedure, therefore, a large difference between the planned and the actual outcomes may be found at these areas.

The present study showed that the mean difference value of the antero-posterior: the vertical: the mediolateral was 1.35: 1.86: 0.85 mm in the maxilla and 2.16: 2.37: 0.91 mm in the mandible. This revealed the overall linear difference

between virtual planning and surgical outcomes of the maxilla was less than those of the mandible in all directions. The results were similar with other studies.^{8,9,12,16} Thus, it may indicate that the use of VSP works better on the maxilla than on the mandible.⁹ A possible explanation of the significant difference in the position of the mandible than the position of the maxilla might be the rotation of the condylar axis after two-jaw orthognathic surgery.¹⁷ In addition, it was found that the overall linear difference in the medio-lateral direction is less than those of other directions in both the maxilla and the mandible. This was 0.85 mm for the maxilla and 0.91 mm for the mandible. It was comparable to the study by Zhang *et al.*⁹ that showed the use of VSP was the best control for the deviation from the midfacial plane.

The success criteria to evaluate the accuracy was set as 2 mm for the linear difference, and 4° for the angular difference in most publications.^{4,10,18} In this study, the mean linear difference in all directions were below 2 mm, which indicated that VSP was an accurate and reproducible tool for treatment planning in 2-jaw orthognathic surgery. Unfortunately, angular differences were not included in

this study. Nevertheless, Kogou *et al.*¹⁶ suggested that the changes in distance were larger than the changes in angle measurement. Thus, the 3D angle measurement was less effective in actual outcome evaluation.

Treatment outcomes of the utilization of VSP in two-jaw orthognathic surgery should include both accuracy and stability. Therefore, a study should compare the preoperative data with immediate, including long-term data after surgery. Nonetheless, numerous publications evaluated the planned positions compared with the actual position immediately after surgery or before orthodontic movement.⁸⁻¹¹ These provided the results about accuracy, but these lacked stable information. Kim *et al.*¹⁴ and Kogou *et al.*¹⁶ evaluated accuracy and stability after orthognathic surgery using 3D planning by comparing plans with early and long-term outcomes. They reported that VSP offered the predicted position of the jaws. Additionally, only minimal change was observed between early and long-term outcomes, this referred to the stability of the maxillary and mandibular positions. Because of these stable positions, some studies reported the results in longer periods without immediate or early postoperative data.^{12,13} They also reported that using VSP is reliable for diagnosis, planning, and manufacture of surgical splints using 3D printing technology. Our study showed the actual treatment outcomes at six-month postoperatively, and the results were concordant with those previous studies.

Landmark identification or reference selection was also an important factor equal to measurement technique. Reference markings on dental structures such as cusp tips were convenient and reproducible. However, dental reference is not reliable in a long-term study because the tooth positions are changed by orthodontic treatment at all time points. Bone references are preferable.¹⁴ This study also measured the differences on the bone at the canine root tip. Presurgical orthodontic adjustments usually created a sufficient incisor overjet, corrected the tooth discrepancy and aided in providing a solid class I

canine relationship at surgery and in the final outcome.¹⁹ The canine should be minimally affected by post surgical orthodontic movement when the class I canine relationship was achieved. However, they still might be influenced by orthodontic treatment. Therefore, most reference points of the present study used the bone references that were negligibly affected by orthodontic movement, so the pre- and postoperative data were compared at the identical landmarks.

All the patients in this study presented with facial asymmetry, an accurate correction was extremely challenging. Furthermore, most of their surgical planning was maxillary canting correction. The correction of the maxillary position is the foundation of two-jaw orthognathic surgery. Failure to do so can lead to poor aesthetic results and remaining facial asymmetry. The accurate presurgical analysis, planning, and surgical technique are required for successful outcomes when the facial asymmetry has been addressed.²⁰ The results of this study demonstrated that the vertical changes were not significantly different between planned and actual outcome at six months after surgery. Also, the more vertical change was not provided the more difference of these values. The results implied that the VSP is one of the well-developed instruments to obtain the satisfactory results for facial asymmetry correction.

The limitation of this study was the availability of CBCT scans. To date, it is not a standard follow up tool for postoperative orthognathic surgery patients. Therefore, it is difficult to perform a prospective study and to gain a large number of study participants. Because of limited resources, the methodology of the present research is mostly dependent on the available CBCT and virtual 3D program in each particular research center. Hence, until a standard 3D-cephalometric analysis is developed, it would be difficult to create a well-constructed research project or accumulate identical information to perform a meta-analysis study. Prospective studies including series CBCT scan and standard pre- and postoperative 3D cephalometric analysis should be further investigated to provide more reliable outcomes.

Conclusion

Regarding the results of the present study, 3D imaging and VSP was a reliable method for two-jaw orthognathic surgery and provided acceptable treatment outcomes. However, the antero-posterior position at the A-point of the maxilla was a sensible position. Further studies should be performed to gain additional data and amend the limitations of the present study.

Acknowledgements

The authors gratefully acknowledge Dr. Sunisa Rochanavibhata for statistical analysis suggestions, and Assoc. Prof. Dr. Somchai Sessirisombat for the permission to include his patients in this study.

Conflicts of interest: No conflict of interest to declare.

References

1. Sharifi A, Jones R, Ayoub A, Moos K, Walker F, Khambay B, *et al.* How accurate is model planning for orthognathic surgery? *Int J Oral Maxillofac Surg* 2008;37(12):1089-93.
2. Schneider D, Kammerer PW, Hennig M, Schon G, Thiem DGE, Bschorer R. Customized virtual surgical planning in bimaxillary orthognathic surgery: a prospective randomized trial. *Clin Oral Investig* 2019;23(7):3115-22.
3. Swennen GR, Mollemans W, Schutyser F. Three-dimensional treatment planning of orthognathic surgery in the era of virtual imaging. *J Oral Maxillofac Surg* 2009;67(10):2080-92.
4. Stokbro K, Aagaard E, Torkov P, Bell RB, Thygesen T. Virtual planning in orthognathic surgery. *Int J Oral Maxillofac Surg* 2014; 43:957-65.
5. Alkhayer A, Piffko J, Lippold C, Segatto E. Accuracy of virtual planning in orthognathic surgery: a systematic review. *Head Face Med* 2020;16(1):34.
6. Chen Z, Mo S, Fan X, You Y, Ye G, Zhou N. A Meta-analysis and Systematic Review Comparing the Effectiveness of Traditional and Virtual Surgical Planning for Orthognathic Surgery: Based on Randomized Clinical Trials. *J Oral Maxillofac Surg* 2021;79(2):471 e1- e19.
7. Kim DS, Woo SY, Yang HJ, Huh KH, Lee SS, Heo MS, *et al.* An integrated orthognathic surgery system for virtual planning and image-guided transfer without intermediate splint. *J Craniomaxillofac Surg* 2014;42(8):2010-7.
8. Gossett CB, Preston CB, Dunford R, Lampasso J. Prediction accuracy of computer-assisted surgical visual treatment objectives as compared with conventional visual treatment objectives. *J Oral Maxillofac Surg* 2005;63(5):609-17.
9. Zhang N, Liu S, Hu Z, Hu J, Zhu S, Li Y. Accuracy of virtual surgical planning in two-jaw orthognathic surgery: comparison of planned and actual results. *Oral Surg Oral Med Oral Pathol Oral Radiol* 2016;122(2):143-51.
10. Hsu SS, Gateno J, Bell RB, Hirsch DL, Markiewicz MR, Teichgraber JF, *et al.* Accuracy of a Computer-Aided Surgical Simulation Protocol for Orthognathic Surgery: A Prospective Multicenter Study. *J Oral Maxillofac Surg* 2013;71(1):128-42.
11. Tucker S, Cevdanes LH, Styner M, Kim H, Reyes M, Proffit W, *et al.* Comparison of actual surgical outcomes and 3-dimensional surgical simulations. *J Oral Maxillofac Surg* 2010;68:2412-21.
12. Zinser MJ, Mischkowski RA, Sailer HF, Zöller JE. Computer-assisted orthognathic surgery: feasibility study using multiple CAD/CAM surgical splints. *Oral Surg Oral Med Oral Pathol Oral Radiol* 2012; 113(5):673-87.
13. Aboul-Hosn Centenero S, Hernandez-Alfaro F. 3D planning in orthognathic surgery: CAD/CAM surgical splints and prediction of the soft and hard tissues results - our experience in 16 cases. *J Craniomaxillofac Surg* 2012;40(2):162-8.
14. Kim JW, Kim JC, Jeong CG, Cheon KJ, Cho SW, Park IY, *et al.* The accuracy and stability of the maxillary position after orthognathic surgery using a novel computer-aided surgical simulation system. *BMC Oral Health* 2019;19.
15. Kim KY, Bayome M, Kim K, Han SH, Kim Y, Baek SH, *et al.* Three-dimensional evaluation of the relationship between dental and basal arch forms in normal occlusion. *Korean J Orthod* 2011;41(4):288-96.
16. Kogou T, Takaki T, Shibahara T. Three-dimensional Analysis and Evaluation in Orthognathic Surgical Cases with Facial Asymmetry. *Bull Tokyo Dent Coll* 2018;59(3):147-61.
17. Kim YI, Cho BH, Jung YH, Son WS, Park SB. Cone-beam computerized tomography evaluation of condylar changes and stability following two-jaw surgery: Le Fort I osteotomy and mandibular setback surgery with rigid fixation. *Oral Surg Oral Med Oral Pathol Oral Radiol Endod* 2011;111(6):681-7.
18. Schouman T, Rouch P, Imholz B, Fasel J, Courvoisier D, Scolozzi P. Accuracy evaluation of CAD/CAM generated splints in orthognathic surgery: a cadaveric study. *Head Face Med* 2015;11:24.
19. Wolford LM, Stevao ELL, Alexander CM, Goncalves JR, Rodrigues DB. Orthodontics for orthognathic surgery. In: Miloro M, Ghali GE, Larsen PE, Waite PD, editors. Peterson's principles of oral and maxillofacial surgery. 3rd ed. Shelton: PMPH-USA; 2011. P. 1263-94.
20. Kongsong W, Rochanavibhata S. Reoperative genioplasty: a 10-year retrospective study. *Oral Maxillofac Surg* 2021; 26(1):91-8. DOI:10.1007/s10006-021-00964-w