

## Evaluation of 20 degree Shifted Radiographs in Endodontic Treatment

La-ongthong Vajrabhaya<sup>1</sup>, Piyanuch Karnasuta<sup>1</sup>, Suwanna Korsuwannawong<sup>2</sup>, Orachorn Thongburan<sup>3</sup>, Nuttapat Suntharapa<sup>1</sup>, Supussorn Netpheng<sup>1</sup>, Teerada Wuttiprasittipol<sup>1</sup>, Suchansinee Leenavong<sup>1</sup>, Maneerat Yanyongchaikit<sup>1</sup>, Ananya Manopinives<sup>1</sup>

<sup>1</sup>Faculty of Dental Medicine, Rangsit University, Pathumthani

<sup>2</sup>Faculty of Dentistry, Mahidol University, Bangkok

<sup>3</sup>Prasat Neurological Hospital and Institute, Bangkok

### Abstract

The aim of this study was to evaluate the frequency of root canal separation on radiographs of mandibular molars taken for determining endodontic treatment working length using a 20° mesial (M) or distal (D) shift jig compared with a perpendicular (0°) angle. Radiographs of 42 human mandibular molars were taken at a horizontal angle of 0°, 20° M shift, or 20° D shift to the tooth. The radiographs were evaluated by two examiners. Seventy-one percent and 73 % of the 20° M shift radiographs were deemed acceptable (separated roots) by the first and second examiner, respectively. In contrast, 54 % and 64 % of the 20° D shift radiographs were acceptable to the first and second examiner, respectively. The strength of agreement from both examiners was at a high level of 0.804-0.904. The percentage of acceptable M and D shift radiographs for each examiner were similar ( $P>0.05$ ) and significantly higher compared with the 0° x-ray beam angle ( $P<0.05$ ). Radiographs taken using either the 20° M or D shift jigs are more likely to have distinct mandibular molar root canal separation when determining the working length for root canal treatment compared with 0° images. The advantage of these jigs is the precise determination of the shifted radiograph angle.

**Keywords:** Endodontic treatment, Radiograph, Twenty-degree angulation

**Received Date:** Nov 21,2017

**Accepted Date:** Mar 6,2018

**doi:** 10.14456/jdat.2018.30

#### Correspondence to:

Piyanuch Karnasuta. Faculty of Dental Medicine, Rangsit University, 52/347 Muang-Ake Paholyothin Road Lak-Hok, Pathumthani 12000

Thailand Tel: 0894998858 Fax: 0229972200 ext. 4321 E-mail: piyanuch.karnasuta@gmail.com

### Introduction

Radiographs are important diagnostic tools for root canal treatment. They are regularly used for determining the appropriate working length to prevent

the extrusion of instruments or necrotic tissue from the root canal apex. If this extrusion occurs, the patient may experience pain or swelling after treatment. The correct

working length also aids in specifying the apical level to which the root canal should be filled. Filling the root canal shorter or longer than the actual root canal length can reduce long-term treatment success.<sup>1</sup> An electronic apex locator (EAL) is used as a standard method to determine the working length for root canal treatment. However, the adjunctive use of radiographs is required to evaluate the root canal system and to determine the appropriate working length of each canal.

Typical radiographs are restricted to two dimensions that cannot determine the bucco-lingual depth of the tooth. However, the buccal and lingual root canals of multiple-rooted teeth, such as lower molars and upper premolars, can be superimposed on radiographs.<sup>2</sup> Gulabivala *et al.*<sup>3</sup> evaluated root canal morphology in Thai mandibular molars, finding that 61 % and 30 % of mandibular first molars had three and four canals, respectively, while 58 % and 17 % of mandibular second molar had three and four canals, respectively.

Changing the angle of the x-ray tube from 90° by moving the tube 15-20° mesially or distally parallel to the horizontal plane of the tooth aided in gaining separation of the root canals that are typically superimposed radiographically.<sup>4</sup> This is due to Clark's rule or the Buccal Object Rule, in which an x-ray beam moves, one object moves either buccally or lingually to the other, resulting in radiographic root canal separation.<sup>5</sup> This helps the dentist in accurately performing endodontic treatment and lowers the risk of over-preparation or under-preparation of the root canal.

During endodontic treatment, the x-ray beam is typically shifted mesially to separate the root canals and determine if the files extend to the apex for shaping and cleaning the root canals. However, in some cases, the root canals did not separate and a new radiograph has to be taken by increasing the angle or shifting the tube distally. This causes an increase of costs and time, as well as exposing the patient to more radiation. Studies have shown that radiographs taken using a 20° or 40° horizontal shift demonstrated separated root canals.<sup>6,7</sup>

Moreover, other studies found that a 20-25° M shift was better compared with a D shift in separating superimposed canals.<sup>8,9</sup>

Although numerous studies have found that M shifted radiographs demonstrate separated root canals, the x-ray tube M shift angle to separate superimposed canals when determining the root canal working length is typically estimated. Because there is no device indicating the exact angle, this estimation can result in a radiograph that may or may not have sufficient root separation. Hence, the radiographs have to be taken again by increasing the shift angle or changing to a distally shifted angle.

The EndoRay II is normally used for endodontic radiographs such as working length determination, because it fits over endodontic files and the rubber dam clamp and is held securely by the patient's teeth. A new jig developed at Rangsit University (patent No. 1703001943) can fix the precise angle for taking radiographs with a 20° D or 20° M shift. This jig can be inserted into the EndoRay II Film Holder (DENTSPLY Rinn, PA, USA). The jig is positioned such that the x-ray beam is shifted 20° distally or mesially from the perpendicular angle on the horizontal plane, decreasing the error from the conventional estimating method. However, there is no report on the percentage of mandibular molar radiographs that demonstrate separated canals when taken using this jig. The present study evaluated the frequency of root canal separation on radiographs taken for determining the working length of lower molars during endodontic treatment using the 20° D shift jig or 20° M shift jig compared with 0°.

## Materials and Methods

The study participants were patients with lower molars (three or four canals) which had been clinically determined to require endodontic treatment and were restorable at the Comprehensive Dental Clinic, Faculty of Dental Medicine, Rangsit University. Teeth with

C-shaped canals were excluded. The study samples consisted of 42 lower molars, which represented root canal separation in radiographic images taken from 0 and shifted 20°. Of these samples, 22 and 20 teeth had three and four canal orifices, respectively. The study protocol was approved by the Ethics Committee of the Research Institute, Rangsit University (RSEC 46/2559).

### 20° Angle Jig Preparations

The 20°Jig accuracy of both the M and D shift angle was verified using an apparatus modified from Martinez-Lozano *et al*<sup>10</sup>. Each jig was soaked in 2 % Super Germiphene (Germiphene Corporation, Brantford, Canada) bactericidal and fungicidal solution for ten minutes, rinsed in distilled water to remove the remaining disinfectant solution, and then dried on sterile gauze before each use.

### Endodontic Treatment Procedures


Under the supervision of the faculty dentists, the undergraduate dental students applied the rubber dam, prepared the access opening, and irrigated the root canal with 2.5 % sodium hypochlorite (M. Dent, Mahidol University, Bangkok, Thailand). After irrigation, a snugly fitted file was placed in each canal, and the EAL Root Zx (J-Morita, Tokyo, Japan) was attached to measure the root canal depth when the file reached

the canal's apical constriction as indicated on the apex locator. Files were then placed in the root canals to the working length as indicated from the EAL and central (0°), M (+20°), and D (-20°) radiographs were taken.

### Radiographic Procedures

The rubber dam frame was removed from the tooth and a film was inserted into the film holder, and the aiming arm was connected to the EndoRay II body along with the aiming ring. This assembly was placed over the tooth such that its position was parallel to the buccal surface of the tooth and the patient was requested to slightly occlude on the assembly and the radiograph was taken in the center position (Fig. 1A).

The M and D radiographs were taken by fitting the 1/3 jig for the lower left molars and the 2/4 jig for the lower right molars to the Endoray II peg. A new film was inserted into the EndoRay II film holder. The 20°M shift jig fitted to the peg of the film holder along with the EndoRay's arm and ring. The assembly was placed over the tooth such that the buccal surface of the tooth was parallel to the film. Then, the M shift radiographs were taken. The D shift radiographs were taken using the same jig as mentioned above, but the other side of the jig was fitted to the film holder peg (Fig. 1B,1C).



**Figure 1** EndoRay assembly with the PLK jig (petty patent No. 1703001943). A) EndoRay assembly for taking radiographs using the central view in the mandibular teeth. B) To shift a right mandibular tooth image 20° mesially, the 2/4 20° M shift jig was inserted in the body of the EndoRay II before connecting the arm to the 2/4 20° M shift jig. C) To shift a right mandibular tooth image 20° distally, the 2/4 20° D shift jig was inserted in the body of the EndoRay II before connecting the arm with the 2/4 20° D shift jig.

### Radiograph processing

Three radiographs were taken from each tooth with varying horizontal angulations 0 (center), +20 (M), or -20 (D) degrees with a PSIX Phosphor Plate Standard Imaging Plate Size2 (SOPRO, La Ciotat, France). The images were exposed using a digital apparatus (GENDEX expert DC, Chicago, IL, USA) set at 65kVp, 7mA, and 0.32s scan time. The radiographs were obtained using a PSPIX2 sopro Imaging plate scanner (SOPRO, La Ciotat, France).

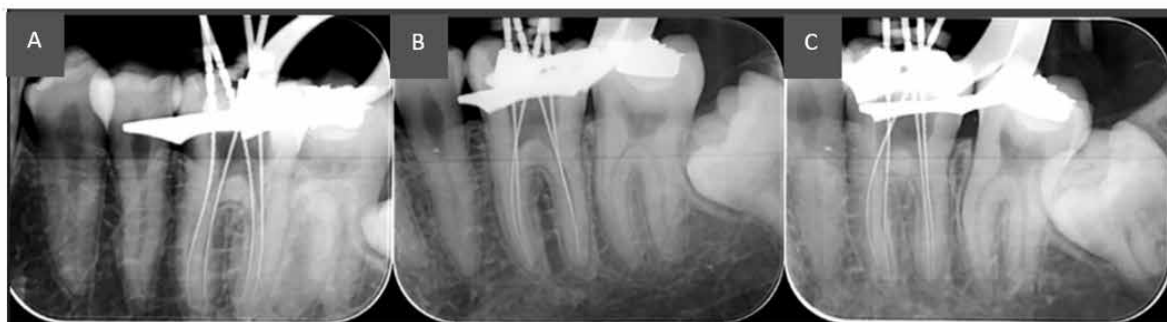### Radiographic image evaluation

The radiographs from each patient were retrieved and arranged using the PowerPoint program. Each set of radiograph were shown at the same

magnification. These images (Fig. 2) were inspected by two endodontic specialists, each with more than ten years of experience. The specialists evaluated the separation of the superimposed root canals on the radiographs obtained during the working length determination. The central, M, and D views were not labeled. The radiographs were evaluated twice (the second time was two weeks after the first evaluation) as either:

0 = Not acceptable (no separation of all superimposed root canals, i.e., another shifted radiograph needed)

1 = Acceptable (distinct separation of all superimposed root canals)



*Figure 2 Representative acceptable and unacceptable radiographic images. Working length determination radiographs of a first mandibular molar (4 canals) taken at different angulations: A = +20°, B = 0°, C = -20°. Score = 1 (A and C), score = 0 (B).*

### Data analysis

The percentage of distinct separated root canals in the 0° (perpendicular to the film), the -20° (D), and +20° (M) shift radiographs were analyzed by each examiner. The strength of agreement between the radiograph evaluations of each examiner (intra and

inter-examiner) was evaluated using Kappa statistics. Finally, significant differences between the percentages of radiographs demonstrating separated root canals based on angle taken as determined by each examiner were analyzed using the Chi-square test. Significance was set at  $P < 0.05$ .

## Results

The forty-two endodontically treated mandibular molars used in this study consisted of thirty-five first molars and seven second molars. The evaluations of the first and the second examiners revealed that the M shift radiographs had the highest percentage of distinctly separated root canals (acceptable) at 71.4 % and 73.8 %,

respectively (Fig. 3). The next highest percentage of acceptable radiographs was demonstrated by the D shift radiographs at 54.8 % and 64.3 %, respectively. The zero degree radiographs had the least percentage of radiographs with separated root canals at 28.6 % and 33.3 %, respectively. The strength of agreement values

of both examiners determined by Kappa analysis were 0.804, 0.889, and 0.940 for the  $-20^\circ$ ,  $0^\circ$ , and  $+20^\circ$  radiographs, respectively. The intra-examiner agreement values of the first examiner were 1.0 for all radiographic angulations and 0.893, 0.850, and 0.877, for the  $-20^\circ$ ,  $0^\circ$ , and  $+20^\circ$  radiographs, respectively, for the second examiner. These results indicate substantial-almost perfect agreement.<sup>11</sup> The statistical analysis of the first examiner's evaluation revealed that the M shift and D shift resulted in a similar percentage of radiographs with an acceptable separation of superimposed canals ( $P=0.113$ ), however both shifts

resulted in a significantly greater percentage of radiographs demonstrating distinct separation compared with the center ( $P=0.000$  and  $0.015$  respectively).

The statistical analysis results of the second examiner's findings were similar, with the M shift and D shift resulting in no significant difference in the percentage of acceptable radiographs ( $P=0.345$ ). Moreover, there was a significantly increased number of radiographs with distinct root canal separation from the  $\pm 20^\circ$  shifts compared with the center view ( $P=0.000$  and  $0.005$ , respectively).

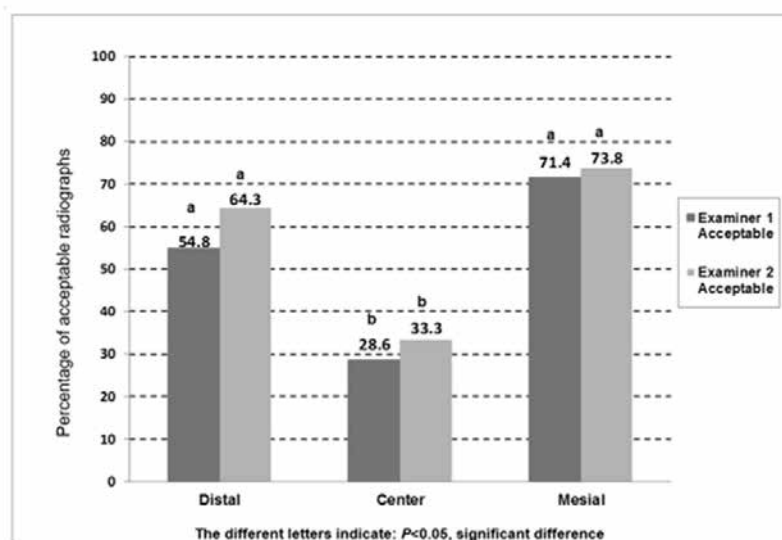


Figure 3 Percentage of acceptable radiographs by the two examiners.

## Discussion

A major difficulty in determining the accurate working length of each root canal in multi-rooted teeth is that the canals are commonly superimposed on the radiographs when using the standard perpendicular technique. The present study investigated the effect of using jigs that produced a  $+20^\circ$  M or  $-20^\circ$  D shift when taking radiographs on generating radiographs with distinct canal separation. These results indicated that the M shift resulted in a greater number of radiographs with distinct root canal separation compared with the D shift when taking radiographs to determine the working

length. Although the M shift and D shift results of both examiners were different from those when using the perpendicular film angle ( $0^\circ$ ), the M and D shift percentages were not statistically different.

A previous study with 120 patients found that a  $20^\circ$  M shift resulted in more radiographs with distinct root canal separation compared with a  $20^\circ$  D shift.<sup>9</sup> However, this study evaluated only molars with four canals. In contrast, our study evaluated 42 mandibular molars, 20 of which had four canals and 22 had three canals. Another study of 25 extracted mandibular first

molar with three roots (radix entomolaris) found that disto-buccal canals superimposed with disto-lingual canals and mesio-lingual canals superimposed with mesio-buccal canals. Among the 0°, 5°, 15°, and 25° radiographs in their study, the 25° mesial horizontal-angled radiographs demonstrated significantly increased root separation compared with radiographs taken using other angulations for identifying superimposed canals.<sup>8</sup> In the present study, a jig was used to fix the tube angle at a 20° M or D shift from the perpendicular when taking radiographs. When determining the working length, a 20° angulation was used based on the results of previous studies<sup>6-8</sup> that demonstrated that this angle resulted in distinct root canal separation. The 20° jig was previously shown to generate +20° or -20° angles from the perpendicular in the horizontal plane for the 20° M shift jig or 20° D shift jig, respectively, when fitted with the EndoRay II. Therefore, using the jig will decrease the frequency of needing to re-take radiographs when determining the working length, master cone fitting, and root canal filling. It is a fundamental principle of radiology that the radiation dose is kept as low as reasonably achievable.<sup>12</sup>

Radiographic image interpretation is another important factor in the present study with the examiners having more than 10 years of experience each in endodontic treatment. The examiners were also calibrated before the study to prevent inter-observer differences; thus, the collected data are reliable. The Kappa scores of both examiners indicated that the strength of agreement (both inter and intra-examiner agreement) were at a substantial-almost perfect level.

The evaluation of the radiographs by examiners 1 and 2 found that 29 % and 33 %, respectively, of the radiographs perpendicular to the film (0°) demonstrated distinct root canal separation. However, the number of acceptable M shift and D shift images were significantly higher compared with the number of acceptable radiographs taken perpendicular to the film. X-ray beams perpendicular to the film occasionally separate the root

canals. This may be because the axis of the tooth is inclined in the mandible, which may cause typically superimposed buccal and lingual root canals to be separated on the radiographic image. However, we suggest that the M shift or D shift is the first choice to use clinically because there is a higher chance of separating the root canals. Because of the sample limitation in the present study, separate evaluation of teeth with of three or four canals to find a suitable shifted direction should be performed.

## Conclusion

Our results indicated that either a 20° M or D shift of the x-ray tube from the perpendicular resulted in a higher percentage of radiographs with distinctly separated root canals compared with a 0° shift. These results suggest that the use of these X-ray tube shifts may result in radiographs that can be more easily interpreted in multiple steps during endodontic treatment, and reduce the number of radiographs that need to be retaken. The advantage of the 20° jig used in this study is that it is useful in determining the precise shifted radiograph angle used in endodontic procedures.

## Acknowledgements

This study was supported by the Junior Project Research Fund of Rangsit University, Thailand.

## References

1. Sjogren U, Hagglund B, Sundqvist G, Wing K. Factors affecting the long-term results of endodontic treatment. *J Endod* 1990;16:498-504.
2. Mohammadi Z, Asgary S, Shalavi S, Abbott P. A clinical update on the different methods to decrease the occurrence of missed root canals. *Iran Endod J* 2016;11:208-13.
3. Gulabivala K, Opananon A, Ng YL, Alavi A. Root and canal morphology of Thai mandibular molars. *Int Endod J* 2002;35:56-62.
4. Walton RE, Found AF. Endodontic radiography. In: Torabinejad

- M, Walton RE, Found AF.(eds) Endodontics Principles and Practice. 5<sup>th</sup> ed., Elsevier Saunders St Louis Missouri 2015;PP203-17.
5. Richards AG. The buccal object rule. *Dent Radiogr Photogr* 1980;53:37-56
  6. Klein RM, Blake SA, Nattress BR, Hirschmann PN. Evaluation of x-ray beam angulation for successful twin canal identification in mandibular incisors. *Int Endod J* 1997;30:58-63.
  7. Haghani J, Raouf M, Pourahmadi S. Ex-vivo evaluation of x-ray horizontal angle for separating the canals of four-canal first mandibular molars. *Iran Endod J* 2008;2:143-6.
  8. Wang Q, Yu G, Zhou XD, Peters OA, Zheng QM, Huang DM. Evaluation of x-ray projection angulation for successful radix entomolaris diagnosis in mandibular first molars *in vitro*. *J Endod* 2011;37:1063-8.
  9. Zhang LD, Chen XW, He Y, Han JL, Wang HN. Evaluation of x-ray beam angulation for successful four canals identification in mandibular first molars. *Shanghai Kou Qiang Yi Xue* 2010;19:354-8.
  10. Martínez-Lozano MA, Forner-Navarro L, Sánchez-Cortés JL. Analysis of radiologic factors in determining premolar root canal systems. *Oral Surg Oral Med Oral Pathol Oral Radiol Endod* 1999; 88:719-22.
  11. Landis JR, Koch GG. The measurement of observe agreement for categorical data. *Biometrics* 1997;33:159-74.
  12. Farman AG. ALARA still applies. *Oral Surg Oral Med Oral Pathol Oral Radiol Endod* 2005;100:395-7.