

Corticotomy-assisted Orthodontic Treatment in Bimaxillary Protrusion Patients

Navarat Voravongsagul¹ and Bancha Samruajbenjakun²

¹Dental Department, Khok Samrong Hospital, Lopburi

²Department of Preventive Dentistry, Faculty of Dentistry, Prince of Songkla University, Songkhla

Abstract

Corticotomy-assisted orthodontic treatment is an option to accelerate orthodontic tooth movement. It also can reduce risks of root resorption, dehiscences and fenestration; increase stability after orthodontic treatment; and expand envelope of tooth movement. In bimaxillary protrusion patients, corticotomy-assisted en-masse retraction can improve malocclusions and prevent side effects from anterior tooth movement beyond the anatomical limit. After a corticotomy, the decreased bone density effects the center of resistance of anterior teeth. The mechanics for en-masse retraction and force systems should be considered for desired anterior teeth movement and control of the posterior segment.

Keywords: Bimaxillary protrusion, Corticotomy, En-masse retraction

Received Date:

Revised Date:

Accepted Date:

doi:

Correspondence to:

Bancha Samruajbenjakun. Department of Preventive Dentistry, Faculty of Dentistry, Prince of Songkla University, Hatyai, Songkhla 90110 Thailand. Tel: 0-7442-9875 E-mail: samruaj@hotmail.com

Introduction

Corticotomy-assisted tooth movement

Alveolar bone remodeling is the key component of orthodontic teeth movement. The idea to accelerate tooth movement is to accelerate bone remodeling. Frost found that bone remodeling increased during wound healing.¹ In 1959 Köle H introduced a corticotomy technique that performed vertical interdental alveolar surgery both buccally and lingually, leaving the medullary bone intact, combined with a horizontal osteotomy cut extending through the entire thickness of the alveolus above the apex of the teeth. He explained rapid tooth

movement after a corticotomy as “bony block movement”. He claimed that this technique could prevent devitalizing of teeth, injury of the periodontium and pocket formation due to the medullary bone remaining intact.² Osteotomy of the cortical layer and subsequent healing should prevent relapse. But this technique was viewed as unnecessarily invasive and was not widely accepted.³

In 2001, Wilcko WM *et al.* introduced a new technique as the Periodontally Accelerated Osteogenic Orthodontics (PAOO, Wilckodontics) procedure that perform full-thickness labial and lingual alveolar flap,

decortication over the facial and lingual surfaces of alveolar bone with bone cuts made barely into the medullary bone that did not injure any tooth or periodontal ligament.⁴ Thicker portions of the alveolar cortex were selectively traumatized to promote bleeding. Combined with augmentation resorbable bone grafting created greater alveolar bone volume, which repaired bony dehiscences and fenestrations and also increased the stability of the orthodontic treatment result. Wilcko MT et al. noted that the increased rate of tooth movement after corticotomy-assisted orthodontics was caused by the increase of bone turnover and the decrease of regional bone density (localized osteopenia) because osteoclasts and osteoblasts were increased by a regional acceleratory phenomenon (RAP) as described by Frost HM.⁵⁻⁷ He found a positive relationship between the intensity of response in the bone healing process and the amount and severity of a corticotomy, the bone turnover rate was increased at the injured region. RAP begins within a few days of surgery, typically peaks at 1 to 2 months, and may take as long as 6 months to 2 years to completely subside. This phenomenon causes bone healing to occur 10-50 times faster than normal bone turnover rate. Actually orthodontic force application alone can also stimulate RAP activity on a mild level. But orthodontic treatment combined with a corticotomy stimulate more RAP.

Of the above information, the advantages of a corticotomy assisted orthodontic treatment can be concluded as follows:

- Reduced treatment time.^{4,6,8,9}
- Decreased risk of root resorption due to reduced treatment duration and decreased resistance of cortical bone.^{4,6,9}
- More stability of the orthodontic outcome is likely due to loss of tissue memory after a corticotomy and the increase in cortical bone thickness due to bone grafting.⁸
- Reduced risk of dehiscence and fenestration from augmentation grafting.²
- The limits of orthodontic tooth movement in adult patients are expanded about two to three-fold for central incisor movement.^{8,10}

Nowadays, a corticotomy technique is widely used to assist orthodontic tooth movement in various purposes with different malocclusions such as to resolve crowding of anterior teeth with shortened treatment time, to accelerate canine retraction after premolar extraction, to enhance post-orthodontic stability, to facilitate eruption of impacted teeth, arch expansion, molar intrusion in open bite cases, intrusion of supraerupted teeth and manipulation of anchorage in molar distalization and bimaxillary protrusion.¹¹

Regarding the adverse effects of a corticotomy, this procedure has no adverse effects on tooth vitality, gingival lines, clinical attachment levels, probing depth and alveolar crestal bone heights because the surgical line is cut about 3 mm below the alveolar crest and not beyond the cortex bone so it barely injures the tooth or periodontal ligament.^{8,12-14} Likewise, root resorption after orthodontic treatment combined with a corticotomy is similar to conventional orthodontic treatment.^{12,15} However because a corticotomy is a surgical procedure, pain and swelling usually occur.

Corticotomy in bimaxillary protrusion patients

A patient with a bimaxillary protrusion is characterized by protrusive and proclined upper and lower anterior teeth which results in the protrusion of the upper and lower lips.¹⁶ A typical orthodontic treatment plan is extraction of the four first premolars and retraction of the anterior segments as maximum to absolute anchorage situation. However, a cortical plate of alveolar bone around the incisors apex acts as a barrier of anterior teeth retraction.¹⁷ Most patients with bimaxillary protrusion have a thin alveolar bone especially in their lower incisors, anterior teeth movement more than anatomical limit may lead to many side effects such as bone dehiscence and fenestration, gingival recession and root resorption.¹⁶ To expand the envelope of tooth movement and prevent risks from this limitation, a corticotomy in the area of anterior teeth is an option besides anterior segmental osteotomy (Fig. 1).

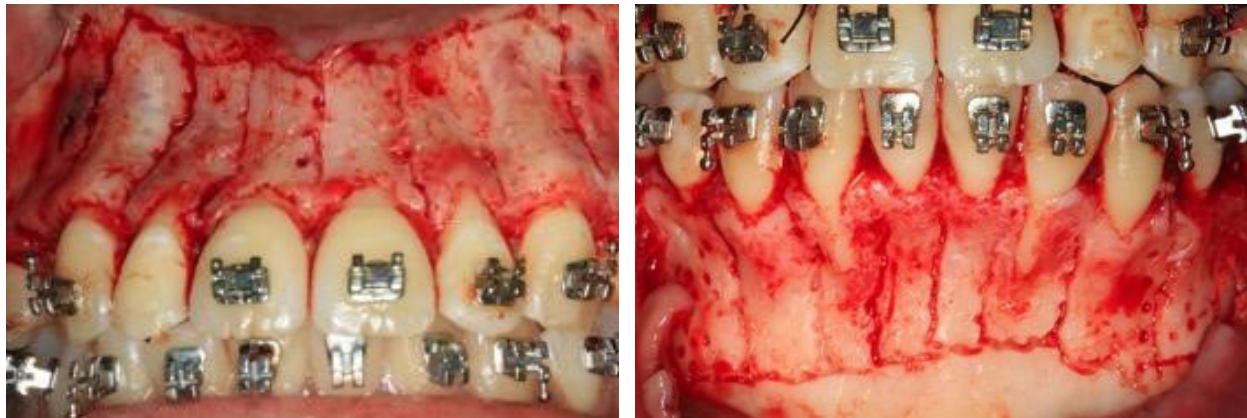

Figure 1 Corticotomy in area of anterior teeth in bimaxillary protrusion patient.

The indications of a corticotomy in bimaxillary protrusion can be concluded as follows:

1. Patients who have a thin alveolar bone housing of upper and/or lower anterior teeth and a treatment plan required anterior teeth retraction more than palatal or lingual bone thickness of the upper or lower incisors.¹⁸ Thin alveolar bone housing exhibits a root prominence in clinical examination. Also alveolar bone thickness is positively correlated with keratinized gingival thickness and width.¹⁹⁻²⁰

2. Patients who have a desire to shorten orthodontic treatment time.²¹⁻²³

The rate of space closure without a corticotomy is 0.8-1.2 mm per month.²⁴⁻²⁶ With a corticotomy, the rate of space closure is twice as fast than conventional treatment (1.8 mm per month in maxilla and 1.6 mm per month in mandible) and the peak of retraction rate is during the first two months that correlate with the RAP phenomenon.^{23,27} The orthodontic treatment time is shortened depending on the rate of tooth movement during RAP phenomenon.

The contraindications of a corticotomy in bimaxillary protrusion can be concluded as follows:⁸

1. Patients who have active periodontal diseases.
2. Patients who have uncontrolled osteoporosis or other bone diseases.
3. Patients who have long-term use of medications that are anti-inflammatory drugs, immunosuppressive drugs, or steroids.

4. Patients who have long-term use of bisphosphonates.

5. Patients who have a gummy smile from vertical maxillary excess and desire to improve their gummy smile.

Retraction of the anterior teeth can be mainly performed by two techniques: two-step conventional technique and en-masse retraction technique. In corticotomy patients, En-masse retraction is usually chosen to retract anterior teeth for the most benefit from RAP that typically peaks at 1 to 2 months after the procedure.

Mechanics for corticotomy-assisted en-masse retraction

En-masse retraction can be done by various orthodontic techniques such as frictionless mechanics (closing loop mechanics) and sliding mechanics (Fig. 2).¹⁸ Due to the protrusion and proclination of the lips and anterior teeth in bimaxillary protrusion patients, temporary anchorage devices (TADs) is widely used for anchorage preparation in en-masse retraction with sliding mechanics.^{21,22,28,29} The retraction force magnitude is 150 grams per side.^{28,29} Following a corticotomy, the activation force initiates immediately or within two weeks after surgery is performed depending on the patients' acceptance and comfort. The force was reactivated every two weeks for lengthening the duration of the RAP effect for 4-6 months (Fig. 3).^{4,6} Suya H recommended a heavier orthodontic force for earlier and faster tooth movement.³⁰ Inversely, Lino S *et al.* suggested that no initial heavy force was necessary.³¹ From previous studies the retraction force after corticotomy

varied from 250 grams to 450 grams per side that could move the teeth effectively without any adverse effects.^{21,23}

However, the optimal force to be applied following a corticotomy is not clear and further studies are needed.

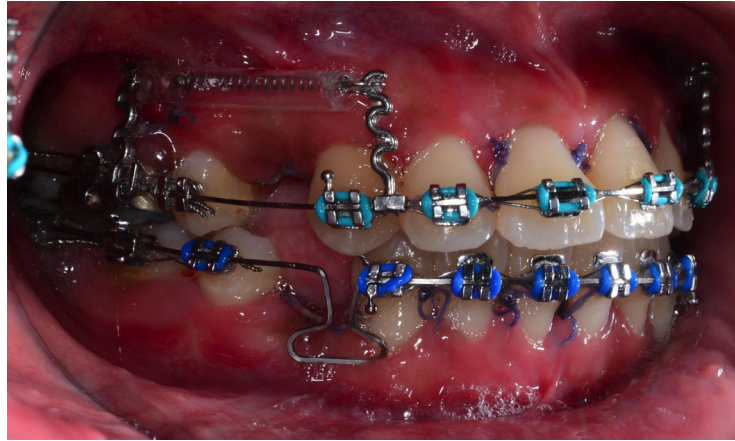


Figure 2 En-masse retraction mechanics, sliding mechanics in upper arch and loop mechanics in lower arch.

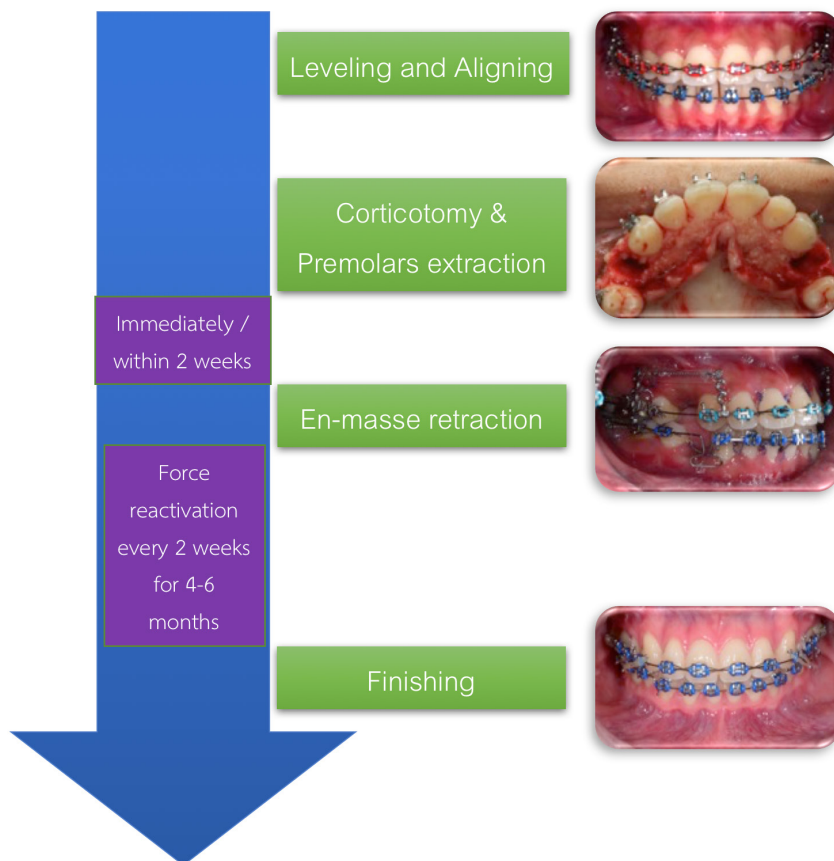


Figure 3 The recommended protocol in corticotomy-assisted orthodontic treatment in patients with bimaxillary protrusion.

Center of resistance of six anterior teeth (CRE) after corticotomy

En-masse retraction is identified by the retraction of the six anterior teeth as one group. From the biomechanical principle, the types of orthodontic tooth movement depend on the relationship between a line of action of the force and the center of resistance (CRE) of the tooth.³² Therefore, the location of the CRE of six anterior teeth is important for treatment planning in the type of anterior tooth movement.

The CRE of the six anterior teeth is determined by various techniques such as laser reflection, *in vivo* study, human autopsy, photoelastic, and finite element method.³³ Among them, the finite element method (FEM) can provide powerful tools for optimizing 3-dimensional (3D) morphology from radiographic scans and determining stress and deflection distributions for complex anatomic geometries such as bone.³⁴ Lee JK and Chung KR reported the location of the CRE of the six upper anterior teeth after the corticotomy was changed more apically than the six anterior teeth without a corticotomy about 0.33 mm.²² This conforms to the study of Ouejiraphant T *et al.* that found the location of the CRE of the six upper anterior teeth after a corticotomy moved 0.2-0.4 mm apically depending on decreased bone density at 5 % to 25 % from the initial value. However, this change was not clinically noticeable.³⁵

Effect of corticotomy to anterior teeth movement

From the effect of corticotomy to the location of CRE of anterior teeth, the incisors tended to move more retroclination, more relative extrusion and the bite deepened after en-masse retraction.^{18,22} This could be an advantage for patients with severe proclination of the upper incisors. However, to minimize these side effects, the retraction force could apply closely to the CRE of the six anterior teeth by using hooks.^{21,23} At present there is no study to compare the inclination of the anterior teeth after en-masse retraction between corticotomy and without corticotomy whether there is clinically significant difference.

From the RAP affect, the retraction rate in corticotomy patients is increased by 2 times during the first two months of retraction compared to the retraction without a corticotomy, resulting in a shorter treatment period.²¹⁻²³ Also Linlawan W *et al.* found that corticotomy-assisted en-masse retraction could retract the anterior teeth beyond the anatomical limit.¹⁸

Corticotomy as anchorage reinforcement

From the study of Sakthi SV *et al.* that compared the amount of molar mesialization after en-masse retraction without TADs or any anchorage devices between corticotomy and without corticotomy, they reported a maximum anchorage situation in corticotomy group and found the anchorage loss in corticotomy group was significantly less than conventional group about 2 times.²³ This could be explained by the uncorticated posterior segment has relatively increase anchorage value compared with decreased bone density of anterior segment. At present there is only one study that evaluate the effect of corticotomy as anchorage reinforcement, further studies are required.

Discussion and Conclusion

Corticotomy-assisted en-masse retraction is an effective treatment option for treating bimaxillary protrusion patients who have a thin alveolar bone of the anterior teeth and/or desire reduced orthodontic treatment time. The decreased bone density after a corticotomy effects the location of CRE of anterior teeth, so the mechanics for en-masse retraction and force systems should be considered for desired anterior teeth movement. Also decreased bone density at the anterior segment can reinforce anchorage of posterior segment when en-masse retraction but further studies are required. The optimal force after a corticotomy is still controversial.

References

1. Frost HM. Wolff's Law and bone's structural adaptations to mechanical usage: an overview for clinicians. *Angle Orthod* 1994;64(3):175-88.

2. Köle H. Surgical operations on the alveolar ridge to correct occlusal abnormalities. *Oral Surg Oral Med Oral Pathol* 1959;12(5):515–29.
3. Proffit WR. Malocclusion and dentofacial deformity in contemporary society. In: Graber TM, Swain BF, ed. *Current orthodontic concepts and techniques*. St.Louis: Mosby, 2005.
4. Wilcko WM, Wilcko MT, Bouquot JE, Ferguson DJ. Rapid orthodontics with alveolar reshaping: two case reports of decrowding. *Int J Periodont Restor Dent* 2001;21(1):9–19.
5. Murphy KG, Wilcko MT, Wilcko WM, Ferguson DJ. Periodontal accelerated osteogenic orthodontics: a description of the surgical technique. *J Oral Maxillofac Surg* 2009;67(10):2160–6.
6. Wilcko MT, Wilcko WM, Bissada NF. An Evidence-Based Analysis of Periodontally Accelerated Orthodontic and Osteogenic Techniques: A Synthesis of Scientific Perspectives. *Semin Orthod* 2008;14(4):305–316.
7. Frost HM. The regional acceleratory phenomenon: a review. *Henry Ford Hosp Med J* 1983;31(1):3–9.
8. Ferguson DJ, Wilcko WM, Wilcko MT. Selective Alveolar Decortication for rapid surgical-orthodontic of skeletal malocclusion treatment. In: William HB, Cesar AG, editors. *BC Decker Inc, Hamilton*; 2007:199–203.
9. Gantes B, Rathbun E, Anholm M. Effects on the periodontium following corticotomy-facilitated orthodontics. Case reports. *J Periodontol* 1990;61(4):234–8.
10. Brugnami F, Caiazzo A. Orthodontically driven corticotomy: tissue engineering to enhance orthodontic and multidisciplinary treatment. In: Mehra P and Shinwari H, ed. *Corticotomy-facilitated orthodontics: surgical considerations*. Pondicherry, India: John Wiley and Sons; 2015:84–86.
11. Hassan AH, Al-Fraid AA, Al-Saeed SH. Corticotomy-assisted orthodontic treatment: review. *Open Dent J* 2010;4:159–64.
12. Shoreibah EA, Ibrahim SA, Attia MS, Diab MM. Clinical and radiographic evaluation of bone grafting in corticotomy-facilitated orthodontics in adults. *J Int Acad Periodontol* 2012;14(4):105–13.
13. Aboul-Ela SM, El-Beialy AR, El-Sayed KM, Selim EM, El-Mangoury NH, Mostafa YA. Miniscrew implant-supported maxillary canine retraction with and without corticotomy-facilitated orthodontics. *Am J Orthod Dentofacial Orthop* 2011;139(2):252–9.
14. Fischer TJ. Orthodontic treatment acceleration with corticotomy-assisted exposure of palatally impacted canines. *Angle Orthod* 2007;77(3):417–20.
15. Shoreibah EA, Salama AE, Attia MS, Abu-Seida SM. Corticotomy-facilitated orthodontics in adults using a further modified technique. *J Int Acad Periodontol* 2012;14(4):97–104.
16. Bills DA, Handelman CS, BeGole EA. Bimaxillary dentoalveolar protrusion: Traits and orthodontic correction. *Angle Orthod* 2005;75(3):333–9.
17. Handelman CS. The anterior alveolus: Its importance in limiting orthodontic treatment and its influence on the occurrence of iatrogenic sequelae. *Angle Orthod* 1996;66(2):95–109;discussion109–10.
18. Linlawan W, Sumruajbenjakun B, Charoemratrote C, Leepong N, editors. A clinical study of corticotomy-facilitated anterior teeth retraction in bimaxillary protrusion patients. \ Proceeding of the 23rd National Graduate Research Conference; 2011. Dec 22–23; Nakorn Ratchasima, Thailand.
19. Fu JH, Yeh CY, Chan HL, Tatarakis N, Leong DJ, Wang HL. Tissue biotype and its relation to the underlying bone morphology. *J Periodontol* 2010;81(4):569–74.
20. Park JH, Hong JY, Ahn HW, Kim SJ. Correlation between periodontal soft tissue and hard tissue surrounding incisors in skeletal Class III patients. *Angle Orthod* 2018;88(1):91–99.
21. Tizini M, Ibrahim G. Retraction of the upper maxillary incisors with corticotomy-facilitated orthodontics and mini-implants. *Saudi J Dent Res* 2014;5(2):146–151.
22. Lee JK, Chung KR, Baek SH. Treatment outcomes of orthodontic treatment, corticotomy-assisted orthodontic treatment, and anterior segmental osteotomy for bimaxillary dentoalveolar protrusion. *Plast Reconstr Surg* 2007;120(4):1027–36.
23. Sakthi SV, Vikraman B, Shobana VR, Lyer SK, Krishnaswamy NR. Corticotomy-assisted retraction: an outcome assessment. *Indian J Dent Res* 2014;25(6):748–54.
24. Dixon V, Read MJF, O'Brien KD, Worthington HV, Mandall NA. A randomized clinical trial to compare three methods of orthodontic space closure. *J Orthod* 2002;29(1):31–6.
25. Barlow M, Kula K. Factors influencing efficiency of sliding mechanics to close extraction space: A systematic review. *Orthod Craniofac Res* 2008;11(2):65–73.
26. Samuels RH, Rudge SI, Mair LH. A comparison of the rate of space closure using a nickel-titanium spring and an elastic module: A clinical study. *Am J Orthod Dentofacial Orthop* 1993;103(5):464–7.
27. Buschang PH, Campbell PM, Ruso S. Accelerating tooth movement with corticotomies: is it possible and desirable?. *Semin Orthod* 2012;18(4):286–94.
28. Aboul-Ela SM, El-Beialy AR, El-Sayed KM, Selim EM, El-Mangoury NH, Mostafa YA. Miniscrew implant-supported maxillary canine retraction with and without corticotomy-facilitated orthodontics. *Am J Orthod Dentofacial Orthop* 2011;139(2):252–9.
29. Upadhyay M, Yadav S, Patil S. Mini-implant anchorage for en-masse retraction of maxillary anterior teeth: A clinical cephalometric study. *Am J Orthod Dentofacial Orthop* 2008;134(6):803–10.

30. Suya H. Corticotomy in orthodontics. In: Hosl E, Baldauf A, eds. *Mechanical and Biological Basis in Orthodontic therapy*. Heidelberg, Germany: Huthig Buch Verlag GmbH; 1991:207-226.
31. Lino S, Sakoda S, Ito G, Nishimori T, Ikeda T, Miyawaki S. Acceleration of orthodontic tooth movement by alveolar corticotomy in the dog. *Am J Orthod Dentofacial Orthop* 2007;131(4):448 e1-8.
32. Nanda R and Kuhlberg A. Principles of biomechanics. In: Nanda R, ed. *Biomechanics in clinical Orthodontics*. Philadelphia, Pa: WB Saunders Company; 1997:1-22.
33. Papageorgiou IS. The center of resistance of teeth in Orthodontics. *Hell Orthod Rev* 2005;8:43-57.
34. Joo JW, Hoe KH, Cha KS. Finite element modeling and the mechanical analysis of orthodontics. *Transaction of Korean Society of Mechanical Engineers (A)* 1999;23:953-958.
35. Ouejaraphant T, Samruajbenjakun B, Chaichanasiri E. Determination of the centre of resistance during en masse retraction combined with corticotomy: finite element analysis. *J Orthod* 2018;45(1):11-5.