

## Prevalence of Maxillary Sinus Septum and Investigation of Morphology in Thai Population by Cone-beam Computed Tomography; Comparative Study between Dentate Partial Edentate and Edentate

Chananchida Cheangcharoon<sup>1</sup>, Thanakrit Naiyawat<sup>1</sup>, Prathomporn Chuchawengwong<sup>1</sup>, Wareeratn Chengprapakorn<sup>2</sup>, Pisha Pittayapat<sup>3</sup>

<sup>1</sup>Faculty of Dentistry, Chulalongkorn University, Bangkok, Thailand

<sup>2</sup>Department of Prosthodontics, Faculty of Dentistry, Chulalongkorn University, Bangkok, Thailand

<sup>3</sup>Department of Radiology, Faculty of Dentistry, Chulalongkorn University, Bangkok, Thailand

### Abstract

The aim of this study was to investigate and compare the maxillary sinus septa and morphology in the Thai population by using cone-beam computed tomography (CBCT) between dentate, partially edentate and edentate patients. CBCT scans from 300 Thai patients: 209 females and 91 males with a mean age of 49.22 years old, were retrospectively collected from the hospital database of the Faculty of Dentistry, Chulalongkorn University, Bangkok, Thailand. All CBCT images were viewed and evaluated on Infinitt<sup>®</sup> software. The evaluation of maxillary sinus septa (type, maxillary sinus wall, location, completion) was performed by two observers. Sixty CBCT scans were randomly selected for re-evaluation after four weeks. Patients' demographic data were recorded. Descriptive analysis of the data was done. A total of 567 maxillary sinuses were included in this study and 241 septa were found. The majority of dentate (60%), partial edentate (59.63%) and edentate (85.71%) groups were found without septa in maxillary sinus. The correlation between dentition and septa was not found. Most septa were located on the medial wall of the maxillary sinus (85.06%), and commonly found in the region of the first and second molars (41.49%). Most maxillary sinuses contained only one septum (88.38%). The septa is mostly attached to the walls of the maxillary sinus (73.03%). Almost 43% (42.74%), of the three-wall-septa attached to the floor, lateral wall and medial wall of the maxillary sinus. The major orientation of the septa was not parallel to sagittal, coronal or horizontal planes (48.96%). The majority of septa completely separated sinus compartments (83.83%). Maxillary sinus septa are common anatomical structures that showed at around 60 – 85% among dentate, partial edentate and edentate patients of the Thai population in this study. They are most often found in the first or second molar region on the floor of the maxillary sinus. These findings are useful information for dentists to prevent possible complications during sinus augmentation procedures.

**Keywords:** Cone-beam computed tomography, Dental implant, Maxillary sinus, Septum

**Received Date:** Jan 22, 2021

**Revised Date:** Feb 9, 2021

**Accepted Date:** Mar 19, 2021

**doi:** 10.14456/jdat.2021.32

**Correspondence to :**

Wareeratn Chengprapakorn, Department of Prosthodontics, Faculty of Dentistry, Chulalongkorn University, 34 Henri-Dunant Road, Pathumwan, Bangkok, 10330 Thailand Tel: 081-755-7558 Email: Wchengprapakorn@gmail.com

## Introduction

Maxillary sinus is a pyramidal shaped cavity extending anteriorly to the canine and premolar area and inferiorly to the first molar region. The size of the sinus increases with age, starting from an insignificant size to an average of 25-35 mm in width, 36-45 mm in height and 38-45 mm in length.<sup>1</sup> The blood supply comes from the infra-orbital artery, the posterior superior alveolar artery and the greater palatine artery.<sup>2</sup> Some anastomoses of the posterior superior alveolar artery and the greater palatine artery can be found at the lateral antral walls. These arteries also supply the Schneiderian membrane of the maxillary sinus.<sup>3</sup> Following tooth extraction, there is a dimensional change of the edentulous area.<sup>4,5</sup> In the posterior maxillary region, there is not only a deficiency in the width and height of the alveolar ridge, but also there is usually the pneumatization of the maxillary sinus which was found to be varied according to tooth type and region. Research showed pneumatization occurs in an area without previous pneumatization. Moreover, previous pneumatization did not favor more pneumatization after tooth extraction.<sup>6</sup> Septa is contained inside some of the maxillary sinuses. Maxillary septa were first described by Underwood in 1910.<sup>7</sup> These septa normally arise from between adjacent teeth and can be found to originate from the floor, the wall or the roof of the sinus.

Nowaday, an osseointegrated dental implant has become readily available for replacing missing teeth. The treatment procedure includes osteotomy of the edentulous area for placement of a dental implant. The common complication found in a dental implant procedure is inadequate bone both in width and height. In order to achieve optimum bone height and width for dental implant placement, a bone augmentation procedure is required. Sinus floor elevation and augmentation is one of the widely used procedures to obtain bone height in the maxillary posterior region. This procedure was first described by Tatum in 1986.<sup>8</sup> The sinus wall is opened at the antral wall and the Schneiderian membrane is lifted to create spaces in between for bone

grafting materials. During the step of exposing the maxillary sinus, perforation of the sinus membrane may occur. This complication is usually associated with the presence of a maxillary sinus septum.<sup>9</sup> Furthermore, there were other intraoperative or postoperative sinus complications such as excessive bleeding, infection, wound dehiscence, sinusitis or loss of bone graft.<sup>9</sup> Therefore, it is necessary to investigate the maxillary sinus septa morphology and pathology by radiographic images prior to the procedure.

Patients with a complete or partial edentulous area are more likely to get dental implant treatment. As a result, the anatomical complication during sinus augmentation surgery will be frequently found in these patients. The correlation between the status of dentition in the posterior maxilla and the presence of sinus septa were not found in the Caucasian population<sup>10</sup> nor in the Taiwanese population.<sup>11</sup> However, this type of data is not available in the Thai population.

Panoramic radiography and cone-beam computed tomography (CBCT) are generally used in dental practice for a preoperative evaluation before placing dental implants.<sup>12</sup> Due to the image geometry and superimposition of anatomical structures, panoramic radiograph may lead to false-positive and false-negative findings in the visualization of septa in almost half of the case studies. False diagnosis of finding maxillary sinus may occur if only panoramic radiography is used.<sup>13,14</sup> CBCT is therefore recommended to obtain a precise preoperative evaluation and three-dimensional visualization of the maxillary sinus.

When using CBCT to investigate maxillary sinus morphology, various orientations and locations of the sinus septa were found in different group populations.<sup>15,16</sup> Nevertheless, there has been no published research on 3D information of maxillary sinus morphology in the Thai population. Therefore, the aim of this study was to investigate the maxillary sinus septum and morphology between dentate, partial edentate and edentate in Thai population by using CBCT.

## Materials and Methods

### *Study design and patient selection*

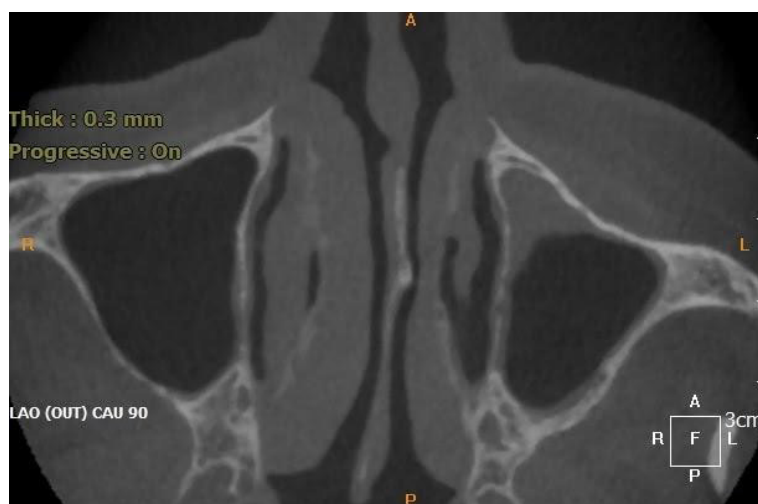The study protocol was reviewed and approved by the ethics committee of the Faculty of Dentistry, Chulalongkorn University (No.064/2019). CBCT images from 1 January 2017- 31 December 2018 were retrospectively collected from the hospital database at the Radiology clinic, Faculty of Dentistry, Chulalongkorn University, Bangkok, Thailand. All CBCT images were screened based on the inclusion and exclusion criteria. CBCT images with a minimum 8x8 mm field of view to cover at least one complete maxillary sinus were included. The exclusion criteria are patients who had a history of surgical intervention or trauma to the maxillary sinus, pathology of the maxillary sinus and the maxillary posterior teeth involving the maxillary sinus (Fig. 1), insufficient image quality. Moreover, the sinuses that exhibited mucosal thickening of more than 4 mm were excluded.

A total of 300 cases were selected with 209 females and 91 males. From these samples, 567 maxillary sinuses (399 sinuses from females and 168 sinuses from males) were included. The maxillary sinuses were divided into three groups (dentate, partial edentate and edentate). Dentate patients include patients with all the teeth present in the selected field of view, partial edentate included

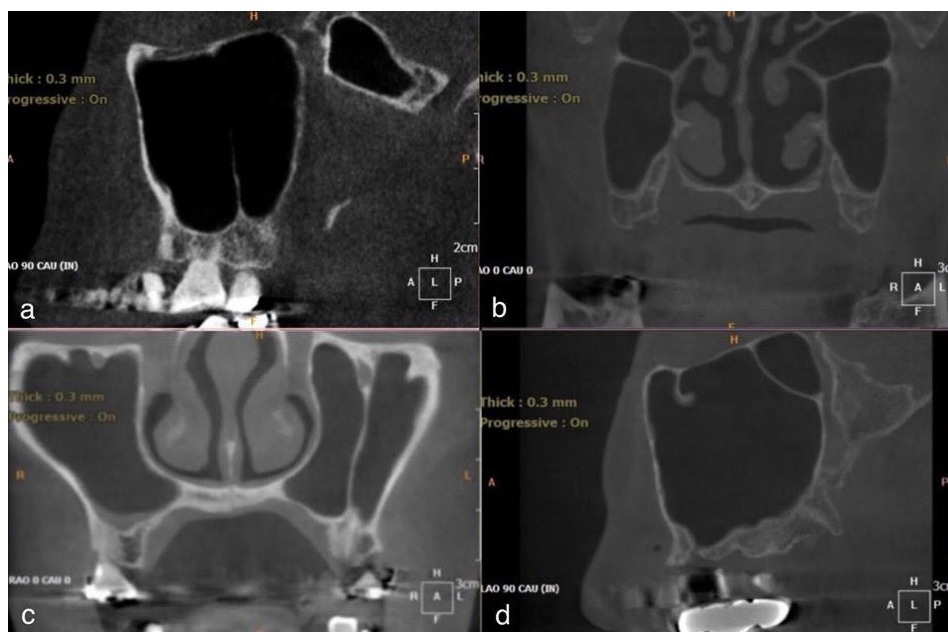
patients with some missing teeth and edentate included patients with no teeth in the field of view. The age group ranged in four groups: 0-20 years old, 21-40 years old, 41-60 years old and more than 60 years old.

### **Radiographic and analysis**

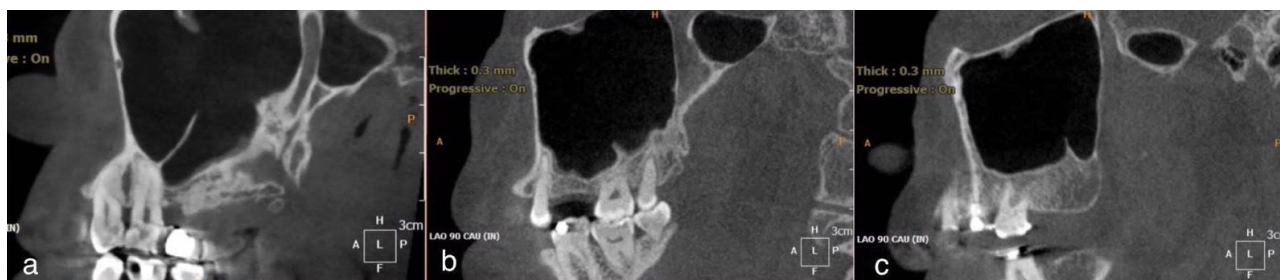All CBCT images were viewed and evaluated on the picture archiving and communication system (PACS) software (Infinitt® software, Infinitt Healthcare Co. Ltd., Seoul, Korea). The parameters regarding patient's data (age, sex, status of dentition of the investigated side: dentate, partial edentulous, edentulous), maxillary sinus septum of more than 2.5 mm in height, type of septa (sagittal, coronal, axial, others) (Fig. 2), the maxillary sinus wall that the septum originated from (floor, roof, medial, lateral, anterior, posterior), the number of septa in the sinus, the location of the septa (anterior: premolar, middle: first and second molar, posterior: third molar) (Fig. 3) and the completion of the sinus (complete: cross one wall to the opposing wall, incomplete) were reviewed from the software by two observers. Prior to the observation, a calibration session to be familiar with the software and the collecting data was performed. Twenty percent of the included CBCT scans were randomly re-evaluated after four weeks.



**Figure 1** An axial CBCT image showed an example of a non-investigated left sinus due to pathology



**Figure 2** Types of maxillary sinus septa: (a) A sagittal CBCT image showed an example of a complete coronal septum in the left maxillary sinus (b) A coronal CBCT image showed an example of a complete axial septum in the left and right maxillary sinus (c) A coronal CBCT image showed an example of a complete sagittal septum in the left maxillary sinus (d) A sagittal CBCT image showed an example of a complete other septum in the left maxillary sinus



**Figure 3** Locations of septa: (a) A sagittal CBCT image showed an example of sinus septa in the anterior region in the left maxillary sinus. (b) A sagittal CBCT image showed an example of sinus septa in the middle region in the left maxillary sinus. (c) A sagittal CBCT image showed an example of sinus septa in the posterior region in the left maxillary sinus

### Statistical analysis

IBM SPSS Statistics software version 22.0 (IBM, Armonk, NY, USA) was used to perform statistical analysis. Descriptive analysis and the frequency of maxillary sinus septa was performed. Any correlation regarding age, dentition, type, location and the present of the sinus septa was calculated using Pearson chi-square tests. Cohen's kappa statistic was performed to evaluate interobserver agreement. The significant level was set at  $p < 0.05$ .

### Results

In this study of 300 patients, 209 patients were females (69.67%) and 91 were males (30.33%) with an average age of 49.22 years old. From these patients, 162 (54%) had at least one septum, and 64 (24%) of the 267 bilateral sinus scan showed septa in both sides. In the 567 maxillary sinuses evaluated, a total of 241 septa were present, and 226 sinuses presented with at least one septum (39.9%). The frequency of sinus presented with at least

one septum for the left and right sides were 38.8% (n = 111) and 40.9% (n = 115), respectively. This finding was statistically significant ( $p < 0.001$ ). Of the total evaluated sinuses, 37.6% (n = 213) had one septum, 2.3% (n = 13) had more than one septum (Table 1).

The samples were categorized into three groups according to the types of dentition on the side that maxillary sinus was investigated. The number of maxillary sinuses with absence and presence of septum in the dentate, the partial edentate and the edentate groups are presented in Table 1. Of the 290 sinuses with dentate (100%), 270 sinuses with partially edentulous (100%) and seven sinuses with completely edentulous (100%), the frequency of sinus presented with at least one septum were 116 sinuses (40%), 109 sinuses (40.37%) and one sinus (14.29%) respectively (Table 3).

Regarding the distribution of sinus septa in relation to the status of the dentition in the left posterior maxilla, septa were present in 49.5% of dentate regions, 50.5% of partially edentulous, and 0% of completely edentulous. For the right posterior maxilla, septa were present in 53% of dentate regions, 46.1% of partially edentulous, and 0.9% of completely edentulous. No significant difference was found for the frequency of septa based on the type of dentition ( $p = 0.358$  and  $p = 0.788$  for the left and right sides, respectively). When comparing between male and female, no statistically significant difference was found ( $p = 0.590$ ). The frequencies of septa in males and females were 51.3% and 55%, respectively (Table 2). Patients were assigned into four age groups. There was also no significant difference in the frequency of septa in relation to the age of a patient ( $p = 0.392$ ) (Table 4).

**Table 1** Frequency sinus septa with regards to types of dentition and sex

| Dentition           | Total sinus<br>By dentition<br>(%) | Sex | Age<br>range (y)      | Total sinus<br>by sex (%) | Number of maxillary sinus |                   |                 |
|---------------------|------------------------------------|-----|-----------------------|---------------------------|---------------------------|-------------------|-----------------|
|                     |                                    |     |                       |                           | No septum<br>(%)          | 1 (%)             | More than 1 (%) |
| Dentate             | 290 (51.1)                         | F   | 10.24 – 84.45 (43.95) | 198 (34.9)                | 113 (19.9)                | 79 (13.9)         | 6 (1.1)         |
|                     |                                    | M   | 11.57 – 70.85 (36.25) | 92 (16.2)                 | 61 (10.8)                 | 29 (5.1)          | 2 (0.3)         |
| Partial<br>edentate | 270 (47.6)                         | F   | 14.06 – 87.19 (57.21) | 196 (34.6)                | 121 (21.3)                | 70 (12.4)         | 5 (0.9)         |
|                     |                                    | M   | 22.51 – 85.18 (56.07) | 74 (13.0)                 | 40 (7.0)                  | 34 (6.0)          | 0               |
| Edentate            | 7 (1.2)                            | F   | 62.36-64.33 (62.93)   | 5 (0.9)                   | 4 (0.7)                   | 1 (0.2)           | 0               |
|                     |                                    | M   | 69.91 – 69.91 (69.91) | 2 (0.3)                   | 2 (0.3)                   | 0                 | 0               |
| <b>Total</b>        | <b>567 (100)</b>                   |     |                       |                           | <b>341 (60.1)</b>         | <b>213 (37.6)</b> | <b>13 (2.3)</b> |

**Table 2** Frequency of patients who have sinus septa with regards to sex

| Sex    | Total patients by sex | Number of patients who have septa (%) |
|--------|-----------------------|---------------------------------------|
| Male   | 91                    | 47(51.6)                              |
| Female | 209                   | 115(55)                               |

**Table 3** Frequency of the maxillary sinus with regards to the number of septa by the dentition

| Dentition        | Total sinus (%) | Number of maxillary sinus (%) |             |
|------------------|-----------------|-------------------------------|-------------|
|                  |                 | No septum                     | ≥1          |
| Dentate          | 290 (100)       | 174 (60)                      | 116 (40)    |
| Partial edentate | 270 (100)       | 161 (59.63)                   | 109 (40.37) |
| Edentate         | 7 (100)         | 6 (85.71)                     | 1 (14.29)   |

Table 4 Frequency of sinus septa with regards to age group

|          | Age group      |                 |                 |                        | Total |
|----------|----------------|-----------------|-----------------|------------------------|-------|
|          | 0-20 years old | 21-40 years old | 41-60 years old | More than 60 years old |       |
| No Septa | 10             | 40              | 42              | 46                     | 138   |
| Septa    | 7              | 38              | 52              | 65                     | 162   |
| Total    | 17             | 78              | 94              | 111                    | 300   |

Types, morphology and locations of maxillary sinus septa

Of the 241 included septa, the most common orientation of septa was coronal (44%; n = 106), followed by axial (4.1%; n = 10) and sagittal (2.9%; n = 7). More than one-third of the septa (49%; n = 118) could not be classified as coronal, sagittal, or axial and were designated as “other”. The most frequently found origin of septa was medial (29.5%; n = 205), followed by floor (24.8%; n = 172), lateral

(24.1%; n =167), roof (8.4%; n = 58), anterior (7.8%; n = 54) and posterior (5.5%; n = 38) (Figure 4). The majority of septa were found in the region of the first or second maxillary molars (41.5%; n = 100), 32.8% (n = 79) were located in the retromolar (posterior) area, and 25.7% (n = 62) were in the premolar area. Of the 241 septa identified, 83.8% (n = 202) were complete and 16.2% (n = 39) were incomplete.

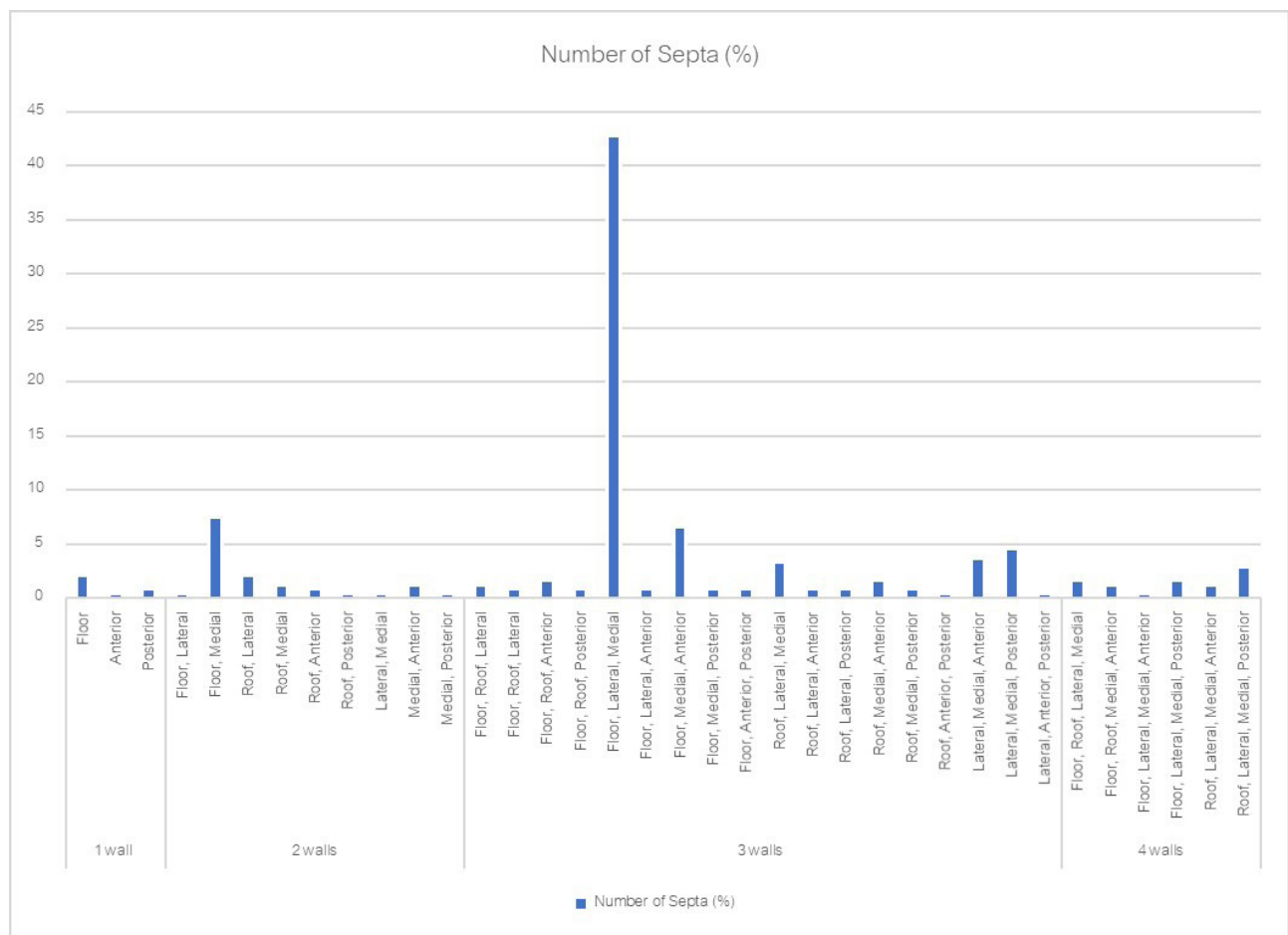


Figure 4 Frequency of sinus septa with regards to origin



The differences in the orientation of the septa in relation to the type of dentition (dentate, partially edentate and edentate) were not statistically significant ( $p=0.571$  and  $p=0.588$  for the left and right sides, respectively). The differences in the location of the septa in relation to the type of dentition were not statistically significant ( $p=0.685$  and  $p=0.614$  for the left and right sides, respectively). In addition, the differences in the completion of the septa

in relation to the type of dentition were not statistically significant ( $p=0.833$  and  $p=0.490$  for the left and right sides, respectively).

#### Observer reliability

The kappa values for both observers were excellent, ranging from 0.983 to 1.00. Substantial interobserver reliability for the type of septa (classified into coronal, sagittal, axial and others) was observed (Cohen's kappa value = 0.983)(Table 5).

**Table 5** Intraobserver reliability (Cohen's kappa values)

| Measurement       | Reliability test                   | Values |
|-------------------|------------------------------------|--------|
| Presence of septa | Cohen's kappa coefficient          | 1.000  |
| Dentition         | Cohen's kappa coefficient          | 1.000  |
| Type of septa     | Cohen's kappa coefficient          | 0.983  |
| Septa completion  | Cohen's kappa coefficient          | 1.000  |
| Septa location    | Cohen's kappa coefficient          | 1.000  |
| Number of septa   | Intraclass correlation coefficient | 1.000  |

## Discussion

This study aimed to investigate the maxillary sinus septa and morphology in the Thai population by using CBCT scans from 300 Thai patients collected from the hospital database of the Faculty of Dentistry. In this investigation, 54 % of the patients had at least one septum and 39.9 % of the sinuses had at least one septum. These findings were lower than results reported by Bornstein *et al*<sup>17</sup>, with septa present in 66.5 % of the patients; 56.5 % of the sinuses, using a similar threshold of 2.5 mm height of sinus septum as our study. However, a systematic review by Pommer, et al which included at least 2-4 mm height of sinus septum demonstrated that septa present in 28.4 % of the sinuses.<sup>18</sup> Different methods have been used to investigate the maxillary sinus septa and morphology in previous studies such as panoramic radiographs, computed tomographic imaging and direct assessment in sinus surgery patients and cadaveric heads.<sup>19-21</sup> Gandhi and others conducted a study of cadaveric heads with at least 2.5 mm in height as a minimal height of maxillary sinus septa and found that 28.1 % of the maxillary sinuses have sinus septa.<sup>22</sup>

Lee and colleagues conducted a study using CBCT images for posterior maxilla with at least 2.5 mm in height as a minimal height of maxillary sinus septa found that 24.6 % of the maxillary sinuses and in 27 % of the total patients have maxillary sinus septa.<sup>19</sup> Park *et al.* and others conduct a study using CT scans with at least 3 mm in height as a minimal height of maxillary sinus septa found that frequency of 37 % of patients and 27.7 % of maxillary sinuses have sinus septa.<sup>20</sup> From the study of Park *et al.*, they reported a higher percentage of maxillary sinus septa even with a higher threshold than Lee *et al.* and Gandhi *et al.* but the frequency was still lower than the current study.<sup>19</sup> The higher threshold may explain the lower frequency of sinus septa compared to the results of this study.

The results of this study was similar to a study conducted by Koymen *et al.*<sup>21</sup> Dental CT images were used to assess 410 sinus segments, it was found that 35.4 % of maxillary sinus had sinus septa.<sup>21</sup> Another study by Qian *et al.* used reconstructed CBCT images of 1,012 sinuses

with at least 2.5 mm in height. It was revealed that the prevalence of septa was 48.2 % based on the number of patients and 32.6 % based on sinuses.<sup>15</sup> In this study, there were no significant differences between the frequency of septa and sex or age and type of dentition (dentate, partially edentulous, edentulous) of the patients. These findings were similar to previous reports.<sup>10,11</sup> However, Pommer *et al.* showed that there was a significant difference of septa between edentulous and dentate ridges. The authors explained that there might be a recruitment bias because radiographic images were collected from a specific patient group who were referred for implant treatment.<sup>17</sup>

The current study revealed that the most common orientation of septa was coronal plane (44 %). These results were in concordance with the study published by Bornstein *et al.*<sup>17</sup>. In this report, the most frequently found origin of septa was the medial wall (29.5 %). In contrast, Bornstein *et al.* showed that most septa were located on the floor of the maxillary sinus (58.6 %). This might be because of the pyramidal shape of the maxillary sinus; therefore, it was hard to identify the exact boundaries between each wall<sup>17</sup>. The first or second maxillary molars region was the area that the majority of the septa was found (41.5 %) and most of the septa were complete (83.8 %). The results also agree with what was reported by Bornstein *et al.*<sup>17</sup> During a lateral window sinus augmentation procedure, the operator has to perform an osteotomy at the lateral of the maxillary sinus. Our study showed a second frequently found origin of septa at the floor and the lateral of the maxillary sinus, therefore, this area should be operated with caution. Sinus perforation is the main complication found during the sinus augmentation procedure especially when replacing a single tooth.<sup>23</sup> Moreover, the most frequent sinus orientation found in our study was in the coronal plane which is perpendicular to the osteotomy site of the sinus augmentation procedure. Without prior information from CBCT, dentists could create a sinus membrane perforation when opening the wall of the sinus.

Prior studies reported data from mostly a Caucasian population, some reports from South Korea and Taiwan

showed prevalence of maxillary septa in the East Asian population.<sup>11,19,24</sup> However, a prevalence of the sinus septa in the South East Asian population was not described previously. Further studies with a larger sample size among a South East Asians population is needed.

Regarding how the number of maxillary sinus septa correlates to sex, our study showed 51.6 % of male and 55 % of female were presented with sinus septa. However, in the Taiwanese population, men have more chances to have septa than women.<sup>11</sup> In a study of edentulous patients, age did not correlate with the presence of sinus septa.<sup>25</sup> Our report showed similar results to the study by Orhan, *et al* in a Turkish population where significant difference was not found among age groups.<sup>26</sup>

The limitations in this research are all radiographic images come from a patient group who were referred for any specific reason such as implant or investigate sinus anomaly so there might be a recruitment bias and some radiographic images have only one side so in this research, we can't collect data of left and right side equally. Moreover, due to the small sample size of the edentate group, our report showed 85.7 % without sinus septa while 14.3 % or one person was found with septa. A larger group of edentulous patients is needed to evaluate the significance of edentulous to the presence of sinus septa. Nevertheless, based on the findings of this study, the reliability of CBCT image analysis was very high. The clinical applications can be drawn from this research that CBCT is recommended for investigation of maxillary sinus before a sinus augmentation procedure.

## Conclusions

Maxillary sinus septa are common anatomical structures and in this study, the Thai population are most often found in the first or second molar region which originated from the medial wall of the maxillary sinus. They are usually completed and parallel to the coronal plane. The majority of the population who have septa showed more than one wall septa. These findings are useful information for dentists to prevent possible complications during sinus augmentation procedures.



## References

1. van den Bergh JP, ten Bruggenkate CM, Disch FJ, Tuinzing DB. Anatomical aspects of sinus floor elevations. *Clin Oral Implants Res* 2000;11(3):256-65.
2. Chanavaz M. Maxillary sinus: anatomy, physiology, surgery, and bone grafting related to implantology—eleven years of surgical experience (1979-1990). *J Oral Implantol* 1990;16(3):199-209.
3. Solar P, Geyerhofer U, Traxler H, Windisch A, Ulm C, Watzek G. Blood supply to the maxillary sinus relevant to sinus floor elevation procedures. *Clin Oral Implants Res* 1999;10(1):34-44.
4. Pietrovski J, Massler M. Alveolar ridge resorption following tooth extraction. *J Prosthet Dent* 1967;17(1):21-7.
5. Hansson S, Halldin A. Alveolar ridge resorption after tooth extraction: A consequence of a fundamental principle of bone physiology. *J Dent Biomech* 2012;3:1758736012456543.
6. Cavalcanti MC, Guirado TE, Sapata VM, Costa C, Pannuti CM, Jung RE, et al. Maxillary sinus floor pneumatization and alveolar ridge resorption after tooth loss: a cross-sectional study. *Braz Oral Res* 2018;32:e64.
7. Underwood AS. An Inquiry into the Anatomy and Pathology of the Maxillary Sinus. *J Anat Physiol* 1910;44(Pt 4):354-69.
8. Tatum H, Jr. Maxillary and sinus implant reconstructions. *Dent Clin North Am* 1986;30(2):207-29.
9. Lee HW, Lin WS, Morton D. A retrospective study of complications associated with 100 consecutive maxillary sinus augmentations via the lateral window approach. *Int J Oral Maxillofac Implants* 2013;28(3):860-8.
10. Schriber M, von Arx T, Sendi P, Jacobs R, Suter VG, Bornstein MM. Evaluating Maxillary Sinus Septa Using Cone Beam Computed Tomography: Is There a Difference in Frequency and Type Between the Dentate and Edentulous Posterior Maxilla? *Int J Oral Maxillofac Implants* 2017;32(6):1324-32.
11. Shen EC, Fu E, Chiu TJ, Chang V, Chiang CY, Tu HP. Prevalence and location of maxillary sinus septa in the Taiwanese population and relationship to the absence of molars. *Clin Oral Implants Res* 2012;23(6):741-5.
12. Wen SC, Lin YH, Yang YC, Wang HL. The influence of sinus membrane thickness upon membrane perforation during transcresal sinus lift procedure. *Clin Oral Implants Res* 2015;26(10):1158-64.
13. Maestre-Ferrin L, Carrillo-Garcia C, Galan-Gil S, Penarrocha-Diago M, Penarrocha-Diago M. Prevalence, location, and size of maxillary sinus septa: panoramic radiograph versus computed tomography scan. *J Oral Maxillofac Surg* 2011;69(2):507-11.
14. Kasabah S, Slezak R, Simunek A, Krug J, Lecaro MC. Evaluation of the accuracy of panoramic radiograph in the definition of maxillary sinus septa. *Acta Medica (Hradec Kralove)* 2002;45(4):173-5.
15. Qian L, Tian XM, Zeng L, Gong Y, Wei B. Analysis of the Morphology of Maxillary Sinus Septa on Reconstructed Cone-Beam Computed Tomography Images. *J Oral Maxillofac Surg* 2016;74(4):729-37.
16. Neugebauer J, Ritter L, Mischkowski RA, Dreiseidler T, Scherer P, Ketterle M, et al. Evaluation of maxillary sinus anatomy by cone-beam CT prior to sinus floor elevation. *Int J Oral Maxillofac Implants* 2010;25(2):258-65.
17. Bornstein MM, Seiffert C, Maestre-Ferrin L, Fodich I, Jacobs R, Buser D, et al. An Analysis of Frequency, Morphology, and Locations of Maxillary Sinus Septa Using Cone Beam Computed Tomography. *Int J Oral Maxillofac Implants* 2016;31(2):280-7.
18. Pommer B, Ulm C, Lorenzoni M, Palmer R, Watzek G, Zechner W. Prevalence, location and morphology of maxillary sinus septa: systematic review and meta-analysis. *J Clin Periodontol* 2012;39(8):769-73.
19. Lee WJ, Lee SJ, Kim HS. Analysis of location and prevalence of maxillary sinus septa. *J Periodontal Implant Sci* 2010;40(2):56-60.
20. Park YB, Jeon HS, Shim JS, Lee KW, Moon HS. Analysis of the anatomy of the maxillary sinus septum using 3-dimensional computed tomography. *J Oral Maxillofac Surg* 2011;69(4):1070-8.
21. Koymen R, Gocmen-Mas N, Karacayli U, Ortakoglu K, Ozen T, Yazici AC. Anatomic evaluation of maxillary sinus septa: surgery and radiology. *Clin Anat* 2009;22(5):563-70.
22. Gandhi KR, Wabale RN, Siddiqui AU, Farooqui MS. The incidence and morphology of maxillary sinus septa in dentate and edentulous maxillae: a cadaveric study with a brief review of the literature. *J Korean Assoc Oral Maxillofac Surg* 2015;41(1):30-6.
23. Krennmair G, Krainhofner M, Schmid-Schwab M, Piehslinger E. Maxillary sinus lift for single implant-supported restorations: a clinical study. *Int J Oral Maxillofac Implants* 2007;22(3):351-8.
24. Kim MJ, Jung UW, Kim CS, Kim KD, Choi SH, Kim CK, et al. Maxillary sinus septa: prevalence, height, location, and morphology. A reformatted computed tomography scan analysis. *J Periodontol* 2006;77(5):903-8.
25. Shibli JA, Faveri M, Ferrari DS, Melo L, Garcia RV, d'Avila S, et al. Prevalence of maxillary sinus septa in 1024 subjects with edentulous upper jaws: a retrospective study. *J Oral Implantol* 2007;33(5):293-6.
26. Orhan K, Kusacki Seker B, Aksoy S, Bayindir H, Berberoglu A, Seker E. Cone beam CT evaluation of maxillary sinus septa prevalence, height, location and morphology in children and an adult population. *Med Princ Pract* 2013;22(1):47-53.