

## Prevalence of *Enterococcus faecalis* and Association with Clinical Characteristics in Teeth Requiring Endodontic Retreatment

Sopida Thipung<sup>1,2</sup>, Anchana Panichuttra<sup>1</sup>, Chootima Ratisoontorn<sup>1</sup>, Somsinee Pimkhaokham<sup>1</sup>, Oranart Matangkasombut<sup>3,4</sup>

<sup>1</sup>Department of Operative Dentistry, Faculty of Dentistry, Chulalongkorn University, Bangkok, Thailand

<sup>2</sup>Maesot Hospital, Tak, Thailand

<sup>3</sup>Department of Microbiology and Center of Excellence on oral microbiology and immunology, Faculty of Dentistry, Chulalongkorn University, Bangkok, Thailand

<sup>4</sup>Research Laboratory of Biotechnology, Chulabhorn Research Institute, Bangkok, Thailand

### Abstract

This study aimed to determine the prevalence of *Enterococcus faecalis* in root canal-treated teeth requiring retreatment and investigate its relationship with clinical parameters and the capacity for biofilm formation. Clinical samples (N=41) from previously root canal-filled teeth that required retreatment were collected using paper points for culture and polymerase chain reaction assay to detect *Enterococcus faecalis*. Clinical and radiographical examinations were performed to assess signs and symptoms, periapical lesions, quality of previous root filling and coronal restorations. Data were analyzed with Fisher's Exact test. The prevalence of *Enterococcus faecalis* was 9.8 % and 75.6 % by culture and polymerase chain reaction techniques, respectively. No significant association was observed between clinical parameters and *Enterococcus faecalis* in root canals ( $p>0.05$ ), but *Enterococcus faecalis* was significantly associated with periapical lesion in cases that did not heal ( $n=19$ ,  $p=0.035$ ). In addition, clinical isolates of *Enterococcus faecalis* showed different levels of biofilm formation as examined by crystal violet staining. In conclusion, *Enterococcus faecalis* was frequently detected in root canal-filled teeth that required retreatment and they showed various levels of biofilm forming capacity.

**Keywords:** Endodontic, *Enterococcus faecalis*, Persistent infection, Retreatment

**Received Date:** Mar 1, 2022

**Revised Date:** Mar 22, 2022

**Accepted Date:** May 2, 2022

**doi:** 10.14456/jdat.2022.47

#### Correspondence to:

Oranart Matangkasombut, Department of Microbiology and Center of Excellence on oral microbiology and immunology, Faculty of Dentistry, Chulalongkorn University, Henri Dunant Road, Pathumwan, Bangkok 10330, Thailand. E-mail: oranart.m@chula.ac.th, Tel: 02-218-8680

### Introduction

Endodontic failures are mainly caused by persistence of microorganisms in the root canal system, activated immune inflammatory response and bone resorption.

Several studies showed that intraradicular infection of the root canal system is the major causes of the endodontic failure.<sup>1</sup>

## Materials and Methods

### Study population

Thirty-five adult patients (41 teeth) who attended the Department of endodontics, Faculty of dentistry, Chulalongkorn University for non-surgical endodontic retreatment were enrolled in the study. The study protocol was approved by the ethics committee of the Faculty of Dentistry, Chulalongkorn University, Bangkok, Thailand (ref.032/2019) in accordance with the Declaration of Helsinki. All participants gave written informed consent before sample collection.

Inclusion criteria included patients with root-filled single root canal or multirrooted teeth with failed treatment at first or second times as determined on the basis of clinical and radiographic examinations with at least one of the following: persistent signs and/or symptoms, such as pain on palpation, pain on percussion, swelling, pus, or sinus tract opening; radiographic evidence of larger periapical lesion or persistent periapical lesion (endodontic therapy completed more than 4 years); and unsatisfactory root canal obturation, such as underfilled > 2 mm. from the radiographic apex, overfilled, had void, or missed canal in cases required new prosthetic restoration. Exclusion criteria included patients who had antibiotic treatment in the previous three months, tooth with periodontal diseases or had probing depth of > 5 mm., and extreme loss of tooth structure such that the tooth could not be isolated with a rubber dam.

### Sample size calculation

The sample size for this study was calculated based on the prevalence of *E. faecalis* in failed endodontic cases by PCR technique according to a previous study<sup>16</sup>, which was 77 %. When using the following formula with error (d) = 0.10, Alpha ( $\alpha$ ) = 0.05,  $Z(0.975) = 1.95996$ , the sample size was 69.

$$n = \frac{z_{1-\frac{\alpha}{2}}^2 p(1-p)}{d^2}$$

However, due to the limitations on the availability of patients who qualified the eligibility criteria, 41

*Enterococcus faecalis* (*E. faecalis*) has been reported as the most commonly isolated species from root canals with endodontic treatment failure<sup>2,3</sup>, but was not the dominant species in others.<sup>4</sup> *E. faecalis* is a non-spore-forming, fermentative, facultative anaerobic Gram-positive coccus.<sup>5</sup> It can form biofilm on root canal dentin, and is resistant to calcium hydroxide; these may be implicated in endodontic treatment failure.<sup>6</sup> *In vitro* studies showed that *E. faecalis* could form biofilm on human dentin in starvation conditions.<sup>7</sup> However, no significant relationship was observed between biofilm formation capability of *E. faecalis* strains and sources of isolates from root canals, oral cavity, or others.<sup>8</sup> In addition, *E. faecalis* also possesses several virulence factors such as, *ace*, *efaA*, *esp*, *gelE*, *asa* and *asa373*.<sup>9</sup> Evidence regarding the association of clinical parameters and *E. faecalis* in root-canal-treated teeth and its virulence factors are still limited. It has been suggested that *E. faecalis* may be associated with signs and symptoms, the presence of apical radiolucent lesion, quality of previous root filling and quality of the coronal restoration.<sup>4,10,11</sup>

Culture-based and molecular techniques have been used to identify microorganisms in cases with endodontic failure. Culture-based techniques have lower sensitivity and could not detect uncultivable phylotypes<sup>5</sup>, while polymerase chain reaction (PCR) is significantly more effective and can detect a higher frequency of *E. faecalis* in the root canal.<sup>11,12</sup> Recent metagenomic studies identified a plethora of bacterial species in the root canals.<sup>15</sup> Although *E. faecalis* was not the most predominant species, it has been found at a greater frequency or proportion in secondary/persistent endodontic infection than in primary infection.<sup>14,15</sup> This suggests that *E. faecalis* may still be a key pathogen in root canals with persistent infection.

Therefore, this study used both culture-based and PCR techniques to investigate the prevalence of *E. faecalis* in root canals requiring retreatment, and examine its relationship with clinical parameters, and the capacity for biofilm formation.

teeth were included in this study. This resulted in an increase in error rate from 10 to 13 %.

### Clinical parameters

Medical and dental history were collected from hospital records, interviews, and clinical and radiographical examinations. The following variables were recorded for each patient: 1) age 2) gender 3) type of tooth 4) absence or presence of the clinical signs and symptoms defined as moderate to severe pain on percussion or palpation or any flare-up 5) absence or presence of periapical lesion 6) size of periapical lesion (the largest dimension in mm) 7) quality of previous root filling which were classified into acceptable and unacceptable (when root canal filling was underfilled > 2 mm from the radiographic apex, overfilled, had void, or missed canal) 8) quality of the coronal restoration which were classified into intact and defective. The intact coronal restorations had adequate seal both clinically and radiographically. In addition, healing of endodontically treated teeth was classified into healed and not healed, based on criteria modified from Friedman and Mor.<sup>17</sup> Teeth with the absence of any clinical signs and symptoms and periapical lesion were classified as healed, while teeth with the presence of any clinical signs and symptoms and/or periapical lesion were classified as not healed.

### Sampling procedures

Sample collection was as described previously with minor modifications.<sup>16</sup> Aseptic techniques were used throughout endodontic procedures. Each tooth was isolated by rubber dam and disinfected with 1.5% tincture iodine, followed by 70% alcohol. Access preparation was carried out using sterile burs with only normal saline solution for irrigation until the root filling was exposed. Coronal gutta-percha was removed by using sterile gate-glidden burs and the apical material was removed by using K-files or H-files or both (Dentsply Sirona, Ballaigues, Switzerland) without using any chemical solvent. Working length was determined using radiographs and an apex locator (Dentaport Root ZX, J Morita, Irvine, CA, USA). Then,

the root canal wall was filed by using K-files (Dentsply Sirona, Ballaigues, Switzerland) at working length to at least size 25. At least 3 sterile paper points were introduced to the working length (a level approximately 0.5 mm short of the root apex) for 60 seconds each. In cases of multi-rooted teeth, samples were collected from all root canals and combined. One of these paper points was collected in cryotubes containing TE buffer (ie, 10 mM Tris-HCl and 0.1 mM EDTA; pH, 7.6), placed on ice, and transferred to the laboratory for PCR analysis, while another one was transferred into brain heart infusion broth (BHI broth; HiMedia Laboratories, Mumbai, India) for culture. Subsequently, all patients received complete root canal treatment and final restorations.

### Microbiology procedures

#### Culture techniques for *E. faecalis* identification

The samples in BHI broth were vortexed and the bacterial suspension was plated on Mitis Salivarius Agar (MSA; Difco™ Mitis Salivarius Agar, Becton, Dickinson and Difco, Chicago, IL, USA) and incubated at 37°C for 24 hours. From each plate, dark blue colonies with smooth surfaces were presumed to be *E. faecalis* and were subcultured. The isolated pure cultures were characterized by Gram's staining and biochemical test using sorbitol fermentation and *Streptococcus faecalis* (SF) broth (reagents from HiMedia Laboratories, Mumbai, India).

#### PCR assay for *E. faecalis* identification

The root canal samples in TE buffer were thawed at 37°C for 10 minutes and vortexed for one minute. The pellets were collected by centrifugation, washed 3 times with 200 µL of MilliQ water, and resuspended in 200 µL of MilliQ water. Then, samples were boiled for 10 minutes, quickly chilled on ice for 5 minutes, and centrifuged at 4°C to remove unbroken cells and large debris. The supernatant was collected and used as the template for PCR amplification.<sup>16</sup>

PCR was performed as previously described using *E. faecalis* species-specific primers (EFLF (5'-GTT TAT GCC GCA TGG CAT AAG AG-3' GenBank accession no. Y18293)

and EFLR (5'-CCG TCA GGG GAC GTT CAG-3' GenBank accession no. Y18293) which produce a PCR amplicon of 310 bp<sup>5,16</sup>; PCR conditions for each primer set were as previously described. The assay was repeated three times and samples with at least 1 positive test result were considered positive.

#### Biofilm formation assay

Biofilm formation assay was performed as previously described.<sup>8,18,19</sup> *E. faecalis* (ATCC29212) and *E. faecalis* clinical isolates (E1-E4) were cultivated overnight in Tryptic Soy Broth (TSB; HiMedia Laboratories, Mumbai, India) at 37 °C, adjusted to give the final optical density at wave length 600 nm ( $OD_{600}$ ) of 0.1, and incubated until log phase ( $OD_{600}$  = 0.4-0.6). The cultures were adjusted to approximately  $10^7$  CFU/ml and inoculated into at 1:100 ratio in 200  $\mu$ l of TSBG (TSB with 0.25% glucose) in 96-well polystyrene microtiter plates. TSBG alone was used as a negative control. After 24 hours of incubation at 37 °C, the supernatant was carefully discarded by using a micropipette, and plates were washed with distilled water to remove unattached cells. Biofilms were fixed with 100  $\mu$ l of 70% methanol for 30 minutes, stained with 100  $\mu$ l of 1% crystal violet solution in water for 15 minutes, and subsequently washed with distilled water. The dye was extracted with 100  $\mu$ l of 30% acetic acid for 10 minutes. The optical density at 570 nm ( $OD_{570}$ ) was measured by using a microtiter plate reader (Bio-Tek, USA). The assay was performed in duplicates and repeated three times. The capacity of biofilm formation of each clinical isolate was calculated into percentage relative to that of *E. faecalis* ATCC29212.

#### Statistical Analysis

Fisher's Exact Test was used to assess the relationship between the prevalence of *E. faecalis* and clinical parameters. All analyses were performed with IBM SPSS statistics for windows, version 22.0 (IBM, Armonk, NY). A P-value of < 0.05 was considered statistically significant.

## Results

A total of 41 samples were collected from 35 patients, 9 males and 26 females, with an age range of 19-74 years (mean,  $49.4 \pm 17.3$  years). Among the 41 samples, 25 were anterior teeth, 13 were premolars and 3 were molars. The teeth were diagnosed as previously treated with normal apical tissue (n=22), asymptomatic apical periodontitis (n=15), symptomatic apical periodontitis (n=3) or chronic apical abscess (n=1). The reasons for retreatment were persistent signs and/or symptoms (n=4), such as pain on palpation, pain on percussion, or sinus tract opening; radiographic evidence of persistent periapical lesion or larger periapical lesion (n=17); unsatisfactory root canal obturation (n=33), such as underfilled > 2 mm from the radiographic apex, had void, or missed canal; and unsatisfactory coronal restoration (n=21), such as leakage in cases requiring new prosthetic restorations.

The prevalence of *E. faecalis* was 9.8 % (4 in 41 teeth) and 75.6 % (31 in 41 teeth) by culture and PCR techniques, respectively. The relationship between *E. faecalis* (as detected by PCR) and clinical parameters is shown in Table 1. When compared to cases without *E. faecalis*, a higher proportion of cases with *E. faecalis* had periapical lesions (48 % vs. 20 %) and had defective coronal restorations (58 % vs. 30 %), but the differences were not statistically significant ( $p > 0.05$ ). Other clinical parameters, including presence of signs and symptoms, size of periapical lesion in radiographs (in cases with periapical lesion, N=17), quality of previous root filling, and healing after endodontic treatment were not significantly associated with the presence of *E. faecalis* in the root canals ( $p > 0.05$ ). Interestingly, when we performed subgroup analysis in cases that did not heal as shown in Table 2 (n=19), we observed a significant association between *E. faecalis* and periapical lesion ( $p = 0.035$ ). The calculated prevalence ratio was 2.0 with 95% confidence interval of 0.75-5.33 ( $p = 0.16$ ).

**Table 1** Relationship of prevalence of *Enterococcus faecalis* and clinical parameters

Clinical Parameters	<i>Enterococcus faecalis</i> (by PCR)		P-value <sup>a</sup>	<i>Enterococcus faecalis</i> (by culture)	
	Yes (n=31) % (n)	No (n=10) % (n)		Yes (n=4) % (n)	
<b>Clinical signs and/or symptoms</b>					
Yes (n=4)	6.5 (2)	20 (2)	0.245	0 (0)	
No (n=37)	93.5 (29)	80 (8)		100 (4)	
<b>Periapical lesion</b>					
yes (n=17)	48.4 (15)	20 (2)	0.152	50 (2)	
No (n=24)	51.6 (16)	80 (8)		50 (2)	
<b>Size of periapical lesion (N=17)</b>					
< 5 mm (n=13)	73.3 (11)	100 (2)	1.000	50 (1)	
≥ 5 mm (n=4)	26.7 (4)	0 (0)		50 (1)	
<b>Quality of previous root filling</b>					
acceptable (n=8)	19.4 (6)	20 (2)	1.000	0 (0)	
unacceptable (n=33)	80.6 (25)	80 (8)		100 (4)	
<b>Quality of the coronal restoration</b>					
intact (n=20)	41.9 (13)	70 (7)	0.159	25 (1)	
defective (n=21)	58.1 (18)	30 (3)		75 (3)	
<b>Healing</b>					
healed (n=22)	51.6 (16)	60 (6)	0.727	50 (2)	
not healed (n=19)	48.4 (15)	40 (4)		50 (2)	

<sup>a</sup>Fisher's Exact Test

**Table 2** Relationship of clinical characteristics and prevalence of *Enterococcus faecalis* in cases that did not heal (n=19)

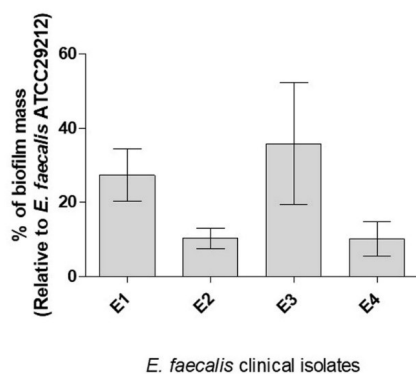
Clinical Parameters	<i>Enterococcus faecalis</i> (by PCR)		P-value <sup>a</sup>
	Yes (n=15) % (n)	No (n=4) % (n)	
<b>Clinical signs and/or symptoms</b>			
Yes (n=4)	13.3 (2)	50 (2)	0.178
No (n=15)	86.7 (13)	50 (2)	
<b>Periapical lesion</b>			
Yes (n=17)	100 (15)	50 (2)	0.035*
No (n=2)	0 (0)	50 (2)	
<b>Size of periapical lesion (N=17)</b>			
< 5 mm (n=13)	73.3 (11)	100 (2)	1.000
≥ 5 mm (n=4)	26.7 (4)	0 (0)	
<b>Quality of previous root filling</b>			
Acceptable (n=5)	20 (3)	50 (2)	0.272
Unacceptable (n=14)	80 (12)	50 (2)	
<b>Quality of the coronal restoration</b>			
Intact (n=11)	46.7 (7)	100 (4)	0.103
Defective (n=8)	53.3 (8)	0 (0)	

<sup>a</sup>Fisher's Exact Test

\*Statistically significant difference (P<0.05)

*E. faecalis* was detected in only four samples using culture methods (Table 1). None of the teeth had any clinical signs and symptoms, but all of the teeth had inadequate root canal filling (underfilled > 2mm. and had void). Two of these samples had periapical lesions of 3 mm and 7 mm in diameter, while the other two were healed with no sign or symptom. Three of these samples had defective coronal restorations (leakage).

To investigate their potential capability for colonization, the four *E. faecalis* isolates were tested for biofilm formation by crystal violet staining assay. The percentage of biofilm mass formed by each of these isolates relative to that of *E. faecalis* ATCC29212, a standard laboratory strain control, is shown in Figure 1. Among these isolates, E3 had the highest biofilm mass (35.9 %±16.5 %), followed by E1 (27.4 %±7.1 %), while E2 and E4 showed similar levels of biofilm formation (10.3 %±2.8 %, 10.1 %±4.7 %, respectively). Interestingly, the isolate with the highest biofilm formation, E3, was the only one isolated from a tooth with intact coronal restoration.



**Figure 1** Average percentage of biofilm formation of *Enterococcus faecalis* clinical isolates (E1-E4) relative to that of a standard laboratory strain (ATCC29212)

## Discussion

In this study, we detected *E. faecalis* in 9.8 % and 75.6 % of endodontically treated teeth requiring retreatment by culture and PCR techniques, respectively. No statistically significant association was observed between *E. faecalis* and any clinical parameters. However, among cases that did not heal, *E. faecalis* was associated with persistent periapical lesion.

In previous reports, the prevalence of *E. faecalis* in root canals with endodontic treatment failure and persistent intra-radicular infection ranged from 30 % to 76 %.<sup>2,3,12</sup> The differences in prevalence among studies were likely attributed to many factors including differences in study population, geographical locations, case selection, sample collection, and detection methods. While previous studies included only root-canal-treated teeth with periapical lesion<sup>2,3</sup> or asymptomatic teeth<sup>2</sup>, this study examined both root-canal-treated teeth with and without periapical lesion, and both with and without symptoms. Recent metagenomic studies detected a wide variety of bacteria in the root canals with primary and/or secondary/persistent infections, with Gram negative bacteria such as *Fusobacterium*, *Prevotella*, *Porphyromonas* among the most abundant.<sup>15,20</sup> Although *E. faecalis* was observed in relatively low abundance, certain studies showed that *E. faecalis* was detected more frequently or at higher proportion in secondary or persistent infection.<sup>15,20,21</sup> Thus, *E. faecalis* may still play a role in persistent infection. In addition, *Enterococcus* is commonly found in teeth with intact coronal restorations suggesting that it may persist in the treated root canals.<sup>21</sup>

Several studies showed that instrumentation and medication cannot completely remove microbial infection from the root canal system.<sup>22,23</sup> The remaining microorganisms, especially those that are able to attach to the root canal dentin and form biofilm, may persist in ramifications, lateral canals, isthmuses, irregular areas or dentinal tubules.<sup>24</sup> *E. faecalis* has the ability to form biofilm, penetrate into dentinal tubules, resist to medication, and survive in low nutrient conditions.<sup>16</sup> They may persist in a viable, but noncultivable (VBNC) state<sup>25</sup>; this may be a reason why we could detect *E. faecalis* much more effectively using PCR than by culture. However, molecular techniques could also detect non-viable cells or free DNA, which do not play a role in pathogenesis.<sup>26</sup> Although molecular techniques are highly sensitive and allow us to examine the presence of multiple microorganisms, including unculturable species, they could not give an information on viability or

activity of the microorganisms that may contribute to pathogenesis.<sup>27</sup> This limitation may be overcome by metatranscriptomics and metabolomics studies in the future.

*E. faecalis* can form dense aggregates or biofilm in root canals.<sup>6,27</sup> *E. faecalis* is capable of producing several virulence factors in the root canal system that enhance adhesion, colonization and biofilm formation. The virulence genes of *E. faecalis* detected in teeth with treatment failure included *ace*, *efaA*, *esp*, *gelE*, *asa* and *asa373*.<sup>9</sup> It was suggested that biofilm formation and extracellular material (ECM) may increase resistance to environmental stresses.<sup>28</sup> In addition, biofilms are significantly associated with large lesions and cysts.<sup>29</sup> Our results showed that different clinical isolates of *E. faecalis* showed different levels of biofilm formation. This may affect their ability to colonize the root canals. Of note, the clinical strain with the highest biofilm mass was isolated from a tooth with intact coronal restoration but with unacceptable quality of previous root filling (void), while the other strains were from teeth with defective restorations. This may imply that the bacteria with high biofilm formation may have persisted from previous treatment. However, due to small sample size, we could not make a conclusion on the association between biofilm formation and clinical parameters, and further studies are needed.

The relationships between *E. faecalis* and clinical parameters in root-filled teeth are still inconclusive.<sup>4,10,11</sup> While Kaufman and colleagues showed that *Enterococcus spp.* significantly associated with the presence of periapical lesion<sup>10</sup>, others did not observe such association.<sup>11</sup> In our study, we found a significant association between *E. faecalis* and periapical lesion only among cases that did not heal (Table 2). However, due to the small sample size, when we calculated the prevalence ratio, the confidence interval was too wide and did not reach statistical significance. Thus, further studies are needed to verify this finding. Another limitation of this study is that we had to use files to remove existing root canal filling materials before sample collection; this may inadvertently remove some of the bacteria in the root canals. In addition, a complex

community of microorganisms likely contributes to persistent infection, and it was suggested that large periapical lesions correlated with higher counts of gram-negative rod species.<sup>4,13</sup> Besides, viruses and fungi have also been associated with endodontic infection.<sup>30</sup> Therefore, the role of multi-species biofilm in persistent infection and relations to clinical parameters should be considered in future investigations.

## Conclusion

*E. faecalis* was detected in approximately 76 % of root canal-treated teeth that required retreatment, using PCR analysis. While *E. faecalis* was not significantly associated with any clinical parameters, it was significantly associated with periapical lesion among cases that did not heal. Clinical strains of *E. faecalis* showed different levels of capability for biofilm formation.

## Acknowledgement

This work was supported by Ratchadaphiseksomphot Endowment Fund (Center of Excellence on oral microbiology and immunology). We would like to thank all the participants in this study and members of the center of excellence on oral microbiology and immunology, Faculty of Dentistry, Chulalongkorn University for generous assistance.

**Conflicts of interest :** All authors declare no conflict of interest.

## References

1. Nair PNR. On the causes of persistent apical periodontitis: a review. *Int Endod J* 2006;39(4):249-81.
2. Peciuliene V, Balciuniene I, Eriksen HM, Haapasalo M. Isolation of *Enterococcus faecalis* in previously root-filled canals in a Lithuanian population. *J Endod* 2000;26(10):593-5.
3. Hancock HH, 3rd, Sigurdsson A, Trope M, Moiseiwitsch J. Bacteria isolated after unsuccessful endodontic treatment in a North American population. *Oral Surg Oral Med Oral Pathol Oral Radiol Endod* 2001;91(5):579-86.
4. Murad CF, Sassone LM, Faveri M, Hirata R, Jr., Figueiredo L, Feres M. Microbial diversity in persistent root canal infections investigated by checkerboard DNA-DNA hybridization. *J Endod* 2014;40(7):899-906.
5. Rocas IN, Siqueira JF, Jr., Santos KR. Association of *Enterococcus faecalis* with different forms of periradicular diseases. *J Endod* 2004;30(5):315-20.

6. Siqueira JF, Jr. Aetiology of root canal treatment failure: why well-treated teeth can fail. *Int Endod J* 2001;34:1-10.
7. Liu H, Wei X, Ling J, Wang W, Huang X. Biofilm formation capability of *Enterococcus faecalis* cells in starvation phase and its susceptibility to sodium hypochlorite. *J Endod* 2010;36(4):630-5.
8. Duggan JM, Sedgley CM. Biofilm formation of oral and endodontic *Enterococcus faecalis*. *J Endod* 2007;33:815-8.
9. Barbosa-Ribeiro M, De-Jesus-Soares A, Zaia AA, Ferraz CC, Almeida JF, Gomes BP. Antimicrobial Susceptibility and Characterization of Virulence Genes of *Enterococcus faecalis* Isolates from Teeth with Failure of the Endodontic Treatment. *J Endod* 2016;42(7):1022-8.
10. Kaufman B, Spangberg L, Barry J, Fouad AF. *Enterococcus spp.* in endodontically treated teeth with and without periradicular lesions. *J Endod* 2005;31(12):851-6.
11. Zoletti GO, Siqueira JF, Jr., Santos KR. Identification of *Enterococcus faecalis* in root-filled teeth with or without periradicular lesions by culture-dependent and-independent approaches. *J Endod* 2006;32(8):722-6.
12. Gomes BP, Pinheiro ET, Sousa EL, Jacinto RC, Zaia AA, Ferraz CC, et al. *Enterococcus faecalis* in dental root canals detected by culture and by polymerase chain reaction analysis. *Oral Surg Oral Med Oral Pathol Oral Radiol Endod* 2006;102(2):247-53.
13. Sánchez-Sanhueza G, Bello-Toledo H, González-Rocha G, Gonçalves AT, Valenzuela V, Gallardo-Escárate C. Metagenomic study of bacterial microbiota in persistent endodontic infections using Next-generation sequencing. *Int Endod J* 2018;51(12):1336-48.
14. Bouillaguet S, Manoel D, Girard M, Louis J, Gaia N, Leo S, et al. Root Microbiota in Primary and Secondary Apical Periodontitis. *Front Microbiol* 2018;9:2374.
15. Keskin C, Demiryürek E, Onuk EE. Pyrosequencing Analysis of Cryogenically Ground Samples from Primary and Secondary/Persistent Endodontic Infections. *J Endod* 2017;43(8):1309-16.
16. Siqueira JF, Jr., Rocas IN. Polymerase chain reaction-based analysis of microorganisms associated with failed endodontic treatment. *Oral Surg Oral Med Oral Pathol Oral Radiol Endod* 2004;97(1):85-94.
17. Friedman S, Mor C. The success of endodontic therapy--healing and functionality. *J Calif Dent Assoc* 2004;32(6):493-503.
18. Zheng JX, Bai B, Lin ZW, Pu ZY, Yao WM, Chen Z, et al. Characterization of biofilm formation by *Enterococcus faecalis* isolates derived from urinary tract infections in China. *J Med Microbiol* 2018;67(1):60-7.
19. Mohamed JA, Huang W, Nallapareddy SR, Teng F, Murray BE. Influence of origin of isolates, especially endocarditis isolates, and various genes on biofilm formation by *Enterococcus faecalis*. *Infect Immun* 2004;72(6):3658-63.
20. Bronzato JD, Bomfim RA, Hayasida GZP, Cúri M, Estrela C, Paster BJ, et al. Analysis of microorganisms in periapical lesions: A systematic review and meta-analysis. *Arch Oral Biol* 2021;124:105055.
21. Zandi H, Kristoffersen AK, Ørstavik D, Rôças IN, Siqueira JF, Jr., Enersen M. Microbial Analysis of Endodontic Infections in Root-filled Teeth with Apical Periodontitis before and after Irrigation Using Pyrosequencing. *J Endod* 2018;44(3):372-8.
22. Sakamoto M, Siqueira JF, Jr., Rôças IN, Benno Y. Bacterial reduction and persistence after endodontic treatment procedures. *Oral Microbiol Immunol* 2007;22(1):19-23.
23. Tang G, Samaranyake LP, Yip HK. Molecular evaluation of residual endodontic microorganisms after instrumentation, irrigation and medication with either calcium hydroxide or Septomixine. *Oral Dis* 2004;10(6):389-97.
24. Ricucci D, Siqueira JF, Jr., Bate AL, Pitt Ford TR. Histologic investigation of root canal-treated teeth with apical periodontitis: a retrospective study from twenty-four patients. *J Endod* 2009;35(4):493-502.
25. Figdor D, Davies JK, Sundqvist G. Starvation survival, growth and recovery of *Enterococcus faecalis* in human serum. *Oral Microbiol Immunol* 2003;18(4):234-9.
26. Spratt DA. Significance of bacterial identification by molecular biology methods. *Endodontic Topics* 2004;9(1):5-14.
27. Abusrewil S, Alshanta OA, Albashaireh K, Alqahtani S, Nile CJ, Scott JA, et al. Detection, treatment and prevention of endodontic biofilm infections: what's new in 2020?. *Crit Rev Microbiol* 2020;46(2):194-212.
28. Yoo A, Rossi-Fedele G, Kidd SP, Rogers AH, Zilm PS. Association between Extracellular Material and Biofilm Formation in Response to Sodium Hypochlorite by Clinical Isolates of *Enterococcus faecalis*. *J Endod* 2018;44(2):269-73.
29. Ricucci D, Siqueira JF, Jr. Biofilms and apical periodontitis: study of prevalence and association with clinical and histopathologic findings. *J Endod* 2010;36(8):1277-88.
30. Mergoni G, Percudani D, Lodi G, Bertani P, Manfredi M. Prevalence of *Candida* Species in Endodontic Infections: Systematic Review and Meta-analysis. *J Endod* 2018;44(11):1616-25.e9.