



Original Article

A Systematic Review of the Effectiveness of Laser Therapy in Prevention of Osteoradionecrosis of the Jaw

Thipok Sombutsirinun^{1,2,3}, Suwat Tanya^{2,4}, Sajee Sattayut^{1,2}

¹Department of Oral and Maxillofacial Surgery, Khon Kaen University, Khon Kaen, Thailand

²Lasers in Dentistry Research Group (LDRG), Khon Kaen University, Khon Kaen, Thailand

³Department of Oral and Maxillofacial Surgery, University of Phayao, Phayao, Thailand

⁴Department of Community Dentistry, Chiang Mai University, Chiang Mai Thailand

Abstract

Osteoradionecrosis of the jaw is an incurable condition. Management of complete healing of the necrotic bone and clinical full mucosal coverage is challenging. Therefore, the prevention of osteoradionecrosis of the jaw is worth considering. There was some evidence of using laser therapy for preventing osteoradionecrosis of the jaw. The purpose of this systematic review was to evaluate the effectiveness of laser therapy in the prevention of osteoradionecrosis of the jaw. A systematic review was conducted on published articles in databases of MEDLINE, Embase, Cochrane Library, Scopus, Google Scholar and Thai-Journal Citation Index Center to identify the eligible studies to compare the effectiveness to prevent osteoradionecrosis of the jaw. The latest search date was 29 May 2022. The included studies were assessed with two independent reviewers by using the Cochrane Risk of Bias Tool for randomized controlled trials or the Joanna Briggs Institute critical appraisal for case reports. Then the data was extracted by using the *Cochrane Handbook for Systematic Reviews of Interventions*. The two reviewers were calibrated. The agreement of assessment between the reviewers was 90 %. There were 24 articles included by title and abstract. Five articles were discarded because of duplication. Of 19 articles, there were four studies; one randomized controlled trial and three case reports, that met the eligible criteria. The level of the bias was low risk. In conclusion, there was a possibility of using laser therapy immediately after extraction to prevent osteoradionecrosis of the jaw by gaining faster tissue coverage. The combinations of using laser therapies; photobiomodulation and photodynamic therapy with antibiotics or pentoxifylline and tocopherol or platelet-rich fibrin allowed favorable clinical outcomes in prevention of osteoradionecrosis of the jaw.

Keywords: Osteoradionecrosis, Jaw, Laser therapy, Photobiomodulation, Photodynamic therapy

Received Date: Aug 4, 2022

Revised Date: Sep 13, 2022

Accepted Date: Oct 31, 2022

doi: 10.14456/jdat.2023.8

Correspondence to :

Sajee Sattayut, Oral and Maxillofacial Surgery, Faculty of Dentistry, Khon Kaen University, 123 Mittraphap Rd., Muang, Khon Kaen, 40002 Thailand. E mail: sajee@kku.ac.th

Introduction

It is a fact that 75% of head and neck cancer patients need radiation therapy either for primary or adjunctive therapy after surgical resection of the tumors.¹ Subsequently, patients have to undertake dental extractions or other oral

surgeries. There is a risk for the patient to develop osteoradionecrosis of the jaw (ORNJ) which is one of the most unmanageable complications of radiation therapy for head and neck tumors.²

From the review by Marx *et al.* ORNJ is defined as an unhealed exposed bone for at least six months in the size of more than 1 cm² in an area involving the field of radiotherapy.³ There was a systematic review and meta-analysis reporting the prevalence of ORNJ in the range of 5% to 15%.⁴ According to a review by Rice *et al.* more than 70% of ORNJ occurred within the first three years after cancer treatment including radiotherapy.⁵ ORNJ was commonly found in the mandible by comparison with the maxilla due to poor vascular supply and high bone density of the mandible.⁵ Several factors including primary tumor sites especially at the tongue and floor of the mouth, cancer staging, radiation dose, radiotherapeutic technique, oral condition, tooth extraction, smoking, drinking and nutritional status were able to increase susceptibility to developing ORNJ.⁶ The clinical presentations of ORNJ varied from an area of exposed bone intra-orally, cutaneous fistula, resorption of the inferior border of the mandible and pathological fracture.⁴ Once ORNJ has occurred, it is very challenging for the medical team to regain the form and function of the jaw to the patient.

There have been several therapies used for treating ORNJ such as conservative treatments⁷, hyperbaric oxygen therapy (HBO), medications comprising pentoxifylline, tocopherol and clodronate (PENTOCLO), surgery⁵ and laser therapy.⁶ Regarding conservative treatments including oral hygiene care and antibiotics, 40% to 60% of patients improved by these treatments.⁷ From the meta-analysis of Leesomprasong *et al.* hyperbaric oxygen therapy provided no statistically significant better healing of tissue coverage of the exposed bone when compared to the no treatment group.⁸ Although, PENTOCLO seemed to gain the efficacy of achieving clinical and radiographic remission of ORNJ, the result needed to be confirmed by prospective randomized studies.⁹ After surgical interventions such as radical resection and immediate well-vascularized tissue flap reconstruction, only 55 of the 108 patients were free from ORNJ.¹⁰ There was a report that proposed the benefit of laser therapy via photobiomodulation (PBM) and antimicrobial photodynamic therapy (aPDT).⁶ This is a novel

treatment for ORNJ due to the prominent property of laser for promotion of wound healing. Laser therapy was used to control ORNJ because it was able to promote the healing of soft tissue coverage for exposed bone in the oral cavity.¹⁰

From the review as mentioned, the clinical outcome of treating ORNJ has been still unpredictable. Moreover, some procedures such as resection of the jaw and extensive surgery may compromise the quality of life of the patient. Therefore, we postulate that prevention is considered to be the best strategy for managing ORNJ. Some interventions have been introduced for the prophylaxis of ORNJ such as hyperbaric oxygen therapy and PENTOCLO. From the systematic review, there was insufficient information to demonstrate that the use of hyperbaric oxygen therapy reduced the incidence of ORNJ.¹⁰ Regarding the use of pentoxifylline and tocopherol, there was a systematic review suggesting a lower incidence of ORNJ in the patients receiving dental extractions following radiation therapy.¹¹ However, both hyperbaric oxygen therapy and PENTOCLO have required a long treatment period and compliance from the patients at least 30 dives of HBO in one and a half month or nine weeks of taking pentoxifylline and tocopherol. The systematic review of El-Rabbany *et al.* reported the prevention of ORNJ by using platelet-rich plasma (PRP), fluoride gel and high content fluoride toothpaste, HBO and antibiotics. There has been no review on laser therapy preventing ORNJ.¹³

Regarding the properties of the laser, this therapy was able to increase cellular proliferation, stimulate protein synthesis, promote angiogenesis, and inhibit electrophysiological activity on the nerves.¹⁰ Laser therapy not only enhances wound healing but also relieves pain. Therefore, it is noted that laser therapy can be a good modality for the prevention of ORNJ. This systematic review was conducted with the aim to evaluate the effectiveness of laser therapy in the prevention of osteoradionecrosis of the jaw.

Materials and Methods

The systematic review was conducted based on the assumption and methods as follows.

Objective: Our objective for this systematic review was to evaluate the effectiveness of laser therapy used for preventing ORNJ. The main process of the systematic review provided by the Cochrane Handbook for Systematic Reviews of Interventions was followed.¹⁴ The assessment of the included article was based on the Cochrane Risk of Bias Tool for randomized controlled trials¹⁵ or the Joanna Briggs Institute (JBI) critical appraisal for case reports.¹⁶

Eligibility criteria: The eligibility criteria were the following:

- Types of studies: The clinical studies or reports which had the goal to evaluate the effectiveness of laser therapy in the prevention of ORNJ in humans published from 2000 to week 5, April 2022 were included. In addition, the studies or reports must be published in Thai or English language.

- Types of participants of the studies: The studies involved patients who had a history of radiation therapy in head and neck regions that required dental extractions or oral surgeries. The studies would be excluded from the systematic review if ORNJ existed before receiving the interventions. However, it was acceptable if ORNJ occurred on a different site from the area where the intervention would be done.

- Types of interventions: The studies of interest would be the ones that used laser therapy to prevent ORNJ. Apart from that, the studies needed to provide laser parameters such as wavelength, power, and time. The interventions could be either given to patients before or after dental extractions or oral surgeries.

- Types of outcome measures: The investigators of the studies had to evaluate the complete wound healing (defined as an absence of clinical signs and symptoms of ORNJ), complete mucosal coverage with no bony exposure, no pain and patient satisfaction.

Search methods for the identification of studies. This systematic review was not registered. Our search strategy for this review was applied up to 29 May 2022, to the following electronic databases which was accessed through Khon Kaen University, namely, MEDLINE, Embase, Cochrane Library, Scopus, Google Scholar, and Thai-Journal Citation Index Center (TCI). Once the articles were identified, the reference lists of the included articles were reviewed

to identify articles that may have been missed in the search. Articles published in Thai and English were included. The keywords used in the search include (Laser therapy) AND (Osteoradionecrosis), (Photobiomodulation) AND (Osteoradionecrosis), (PBM) AND (ORN), (Laser therapy) AND (Osteoradionecrosis of the jaw), (Photobiomodulation) AND (Osteoradionecrosis of the jaw), กระตุกตาย (in Thai), เลเซอร์ (in Thai). The exploration of the references of each article was also performed to include more studies.

Study selection and data extraction. Two reviewers (T.S. and S.T.) independently conducted study selection and data extraction. Before selecting publications, T.S. and S.T. calibrated the criteria of selection with S.S. Then each reviewer independently reviewed the titles and abstracts of the studies to include the eligible studies. The data extraction form was designed with guidance from the Cochrane Handbook for Systematic Reviews of Interventions version 6.3.¹⁴ Disagreements were solved by discussion. The senior reviewer was involved when the disagreements remained unclear. The following data was collected:- type of study, subject, control, intervention and outcome.

Assessment of risk of bias and certainty of evidence. The risk of bias was assessed in the selected studies by using either the Cochrane Risk of Bias Tool for randomized controlled trials¹⁵ or the Joanna Briggs Institute (JBI) critical appraisal for case reports.¹⁶ The calibration of applying these assessments was also conducted among the authors. Two reviewers (T.S. and S.T.) independently graded the studies into a “low”, “unclear”, or “high” risk of bias for the Cochrane Risk of Bias Tool¹⁵ and “Yes”, “No”, “Unclear”, or “Not applicable” for the JBI critical appraisal.¹⁶ The reviewers solved disagreements by seeking consensus or consultation with a senior reviewer (S.S.). GRADE system was used to assess the certainty of the evidence for the main outcome. The certainty of the evidence was classified as high, moderate, low, or very low.¹⁷⁻¹⁸

Results

According to the methods of conducting this systematic review, there were 24 articles from the electronic search and no related article from the reference search.

After the removal of duplicates, there were 19 articles. These articles were independently reviewed by 2 reviewers (T.S. and S.T.) in order to screen the titles and abstracts. Out of 19 articles, 14 were discarded because they did not meet the inclusion criteria. The 14 excluded articles were related to the treatments or management of ORNJ only

and had no information about prevention. Furthermore, there was one article¹⁹ that the full paper could not be found. Finally, four articles²⁰⁻²³ that met the inclusion criteria were included in our systematic review. The number of articles per process of searching, screening and selection is shown in Figure 1.

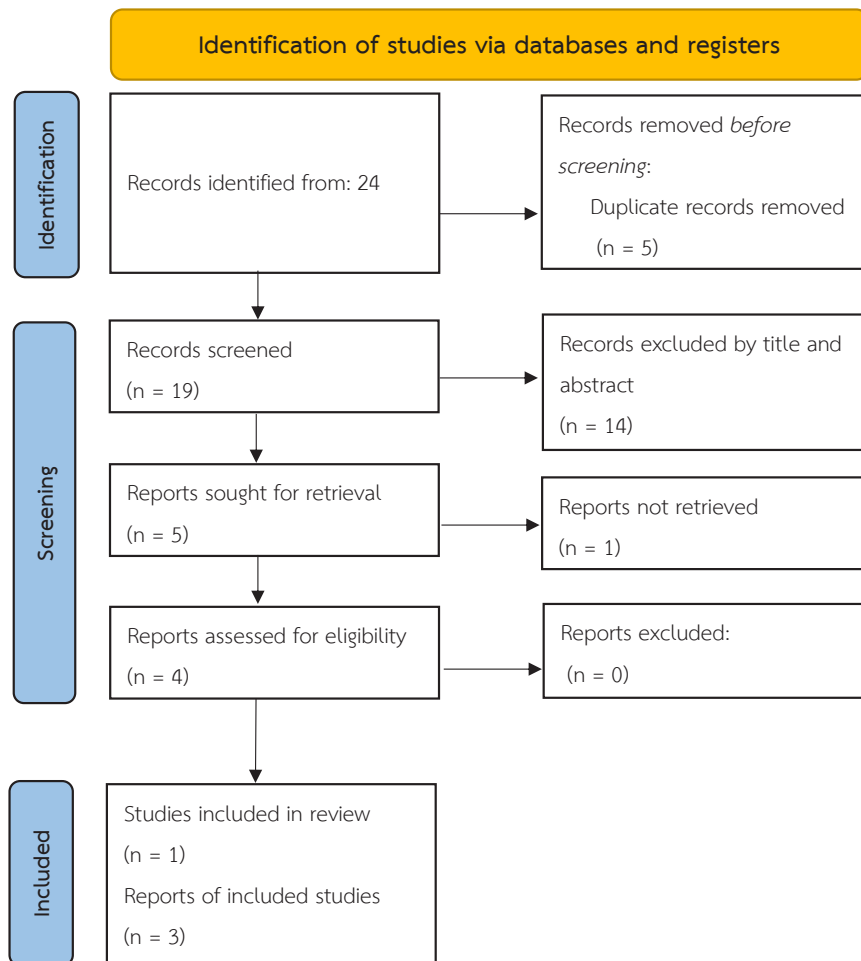


Figure 1 The flow chart of database searching, screening, and selection. There were 5 retrieved studies (Da Silva et al. 2020, Magalhaes et al. 2020, Tateno RY et al. 2020, Franco T et al. 2017, Moreschi et al. 2016)

The included articles were one randomized controlled trial²⁰ and three case reports.²¹⁻²³ The agreement of assessment between the two reviewers was 90%. The results of the risk of bias assessment are shown in Figure 2. The study of Da Silva et al. which was a randomized controlled trial study showed a low risk of bias overall. This study achieved a low risk of bias in four domains and some concern in the domain of selection of the reported result (Figure 2).

The assessment of the case reports is shown in Figure 3. The evaluation of the case report of Magalhaes

IA et al. was considered as low risk of bias as comprising 5 yes, 2 unclear, and 1 not applicable. The case report of Tateno RY et al. had a low risk of bias due to achieving 6 yes, 1 unclear, and 1 not applicable. The case report of Franco T et al. was evaluated as low risk of bias comprising 7 yes and only one unclear.

The certainty of evidence was only assessed from the included RCT (Table 10). It was a moderate certainty. The extracted data is shown in Table 2.

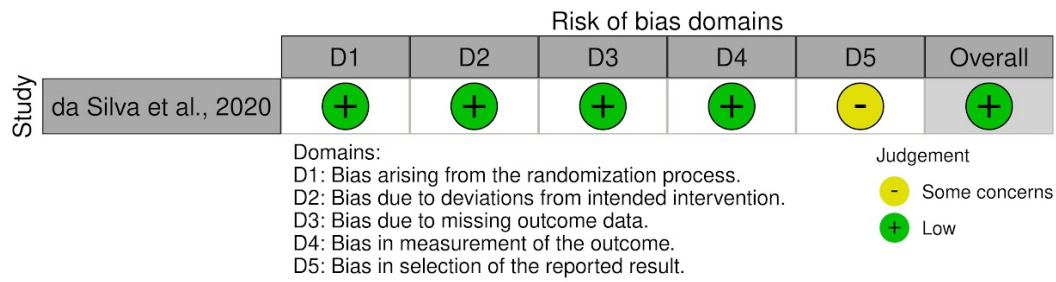


Figure 2 The risk of bias of the randomized controlled trial evaluated by using Cochrane Risk of Bias Tool for randomized controlled trials

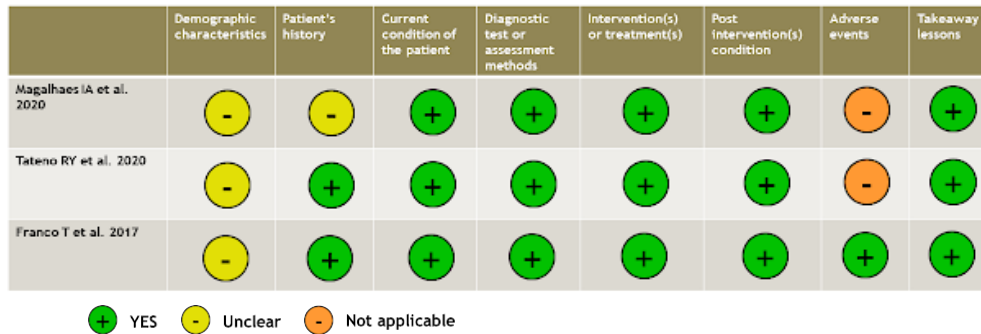


Figure 3 The risk of bias of the case reports evaluated by using JBI critical appraisal for case reports

Table 1 Summary of findings: Laser therapy in prevention of osteoradionecrosis of the jaw (ORNJ)

Laser therapy in prevention of osteoradionecrosis of the jaw (ORNJ)						
Patient or population: patients at risk of developing ORNJ						
Setting: Hospital						
Intervention: Laser therapy with antibiotics						
Comparison: sham laser with antibiotics						
Outcomes	Anticipated absolute effects* (95% CI)		Relative effect (95% CI)	No of participants (studies)	Certainty of the evidence (GRADE)	Comments
	Risk with sham laser	Risk with Laser therapy				
Incidence of ORNJ (mucosal coverage)	At day 14, laser therapy significantly improved mucosal coverage 18/19 sites compared to 0/21 in the control group (RR 0.053, 95%CI 0.008 to 0.355, $p < 0.001$). There is no difference in mucosal coverage on day 28.		Not estimable	40 (1 RCT)	⊕⊕⊕○ Moderate ^a	Laser therapy (PBMT) seems to speed up the epithelization of the extraction sockets compared to sham lasers.

*The risk in the intervention group (and its 95% confidence interval) is based on the assumed risk in the comparison group and the relative effect of the intervention (and its 95% CI).

CI: confidence interval

GRADE Working Group grades of evidence

High certainty: We are very confident that the true effect lies close to that of the estimate of the effect.

Moderate certainty: We are moderately confident in the effect estimate: the true effect is likely to be close to the estimate of the effect, but there is a possibility that it is substantially different.

Low certainty: Our confidence in the effect estimate is limited: the true effect may be substantially different from the estimate of the effect.

Very low certainty: We have very little confidence in the effect estimate: the true effect is likely to be substantially different from the estimate of effect.

a. downgraded 1 level due to serious indirectness (both intervention and control groups were combined with antibiotics)

Table 2 The summary of data extracted from the selected articles

Study	Type of study	Participants	Control/compared treatment	Intervention including setting	Outcome
Da silva <i>et al.</i> 2020	RCT	n=40 Mean (SD) age: 57.05 (10.75) Sex (%male): 63.6%	n=21 Extraction + sham-PBMT+Amoxicillin	n=19 Extraction + PBMT using diode laser 808 nm, 40 mW, 100 J/cm ² , 70s at Day 0, Day 7, Day 14 and Day 21 + Amoxicillin	PBMT had a significant positive effect on both post-operative pain (NNT=2.192, CI95%=1.372-5.445) and mucosal healing (NNT=1.056, CI95%=0.954-1.181). No incidence of ORNJ
Magalhaes <i>et al.</i> 2020	Case report	58-year-old male		A) Extraction & enucleation of periapical cyst B) Amoxicillin and Clindamycin or Metronidazole C) Diode laser (Immediately after the surgical procedure. In addition, one aPDT and three PBMT were performed weekly for 1 month) D) aPDT (using methylene blue and red light 660 nm, 100mW, 90s)	From clinical and radiographic examinations performed after 1, 4, and 12 months, there was no incidence of ORNJ.
Tateno RY <i>et al.</i> 2020	Case report	62-year-old male		A) Extraction & alveoloplasty with primary closure B) Clindamycin C) PBMT 660 nm and 808 nm, 100 mW, 1 J/point, in contact mode (Immediately after the surgical procedure was done and then once/week for 30 days) E) aPDT (using 0.01% methylene blue and red light 660 nm, 5J/point)	During follow-up of 1 year, there was no recurrence of bone necrosis or sequestration and no infection. The patient was asymptomatic and had normal oral functions.
Franco T <i>et al.</i> 2017	Case report	16-year-old female	A) PRF then suturing B) Amoxicillin with clavulanic acid, pentoxifylline, tocopherol, chlorhexidine MW C) PBMT 808nm, 100mW, 0.0028cm ² , 2 J (Immediately after surgical procedure was done)		The extraction sockets were completely healed. The patient did not report any post-operative pain, edema, or other significant side effects.

*RCT=randomized control trial, NNT (number needed to treat), PRF (platelets rich fibrin)

In the four included articles, it was found that the investigators used the following treatments for the prevention of ORN.

1. Photobiomodulation (PBM) and amoxicillin.

The study of da Silva *et al.* compared the effectiveness of PBM using diode laser and amoxicillin in the prevention of ORNJ in patients submitted to dental extraction after head and neck radiation therapy.²⁰ The patients were divided into two groups which were PBMT and sham-PBMT. The intervention group received PBM by using an 808 nm diode laser at 40mW, 100 J/cm² and 70 seconds on days 0, 7, 14, and 21. However, all patients received amoxicillin and surgical debridement to promote primary closure of the surgical site. The PBMT group showed faster mucosal healing (NNT = 1.056, CI95% = 0.954-1.181) and less post-operative pain (NNT = 2.192, CI95% = 1.372-5.445) than the other group.

2. Photobiomodulation, photodynamic therapy and antibiotics.

Magalhaes *et al.* reported on a 58-year-old male patient with a history of radiotherapy to the head and neck region exhibiting a periapical cyst and multiple root remnants.²¹ The PBMT using a 660 nm diode laser at 100 mW, 35 J/cm², 10 seconds was immediately irradiated after the surgical procedure. The patient also received three PBMT weekly for three weeks and one aPDT by using methylene blue as a photosensitizer and 660 nm at 100mW, 90 seconds as an activator. In addition, 21 days of amoxicillin followed by seven days of clindamycin or metronidazole was prescribed. 0.12% chlorhexidine mouthwash was prescribed until the complete tissue coverage of the surgical wound. From 12 months of follow-up, there was no recurrence of ORNJ.

Tateno RY *et al.* reported on a 62-year-old male patient with a history of squamous cell carcinoma at the base of the tongue undertaking radiation therapy for 35 fractions of 2 Gy. After one year of cancer treatment, he developed generalized radiation-induced dental caries. Thereby, the dentist performed full mouth extraction.²² The total number of 17 teeth were removed under general

anesthesia. Removing bone roughness and primary closure was achieved. Immediately after the surgical procedure, PBMT by using 660 and 880nm diode lasers at 100 mW, 1 J/point together with aPDT by using methylene blue and red light 660 nm at 5 J/point were undertaken. The patient also received the combination of PBMT and aPDT once a week for 30 days. During the follow-up period of one year, there was no recurrence of bone necrosis or sequestration as well as infection. The patient was asymptomatic besides normal oral functions.

3. Photobiomodulation, platelet-rich fibrin (PRF) and antibiotics

Franco T *et al.* reported on a 16-year-old female patient who was sent to the dentist for extraction of teeth 37,38 (mandibular left second and third molars) due to advanced external root resorption. She had a history of mucoepidermoid carcinoma at the left parotid gland and received conventional radiotherapy with a total dose of 70 Gy in 35 sessions five years ago.²³ The medications including 0.12% chlorhexidine mouthwash, antibiotic (amoxicillin with clavulanic acid 875mg, twice a day), pentoxifylline (400mg, twice a day) and tocopherol (1000 IU) once daily were prescribed. The patient took those medications one week prior to the surgery and continued the antibiotics for one week and pentoxifylline with tocopherol for eight weeks. After the teeth were extracted, PRF membranes collected from the patient's blood were placed in the sockets. After suturing, PBMT by using an 808 nm diode laser at 100 mW, 0.0028 cm², 2 J was irradiated. The extraction sockets were completely healed. The patient did not report any post-operative pain, edema, or any other significant side effects.

Discussion

Based on the assumption of our systematic review, only one randomized controlled trial met the criteria. The main result of this study showed that the mucosal healing of the group receiving PBM was faster than the other group which received sham PBM. It was noticed that both groups received amoxicillin.²⁰ For the case reports²¹⁻²³ showing favorable results, the combination of laser therapy either

PBM or aPDT and antibiotic medications or pentoxifylline and tocopherol or PRF was employed. However, the duration and dose of antibiotics or pentoxifylline and tocopherol taken were not less than the routine protocol.

Regarding the protocol of providing laser therapy in particular photobiomodulation, all of the studies started lasering the patients just immediately after the surgical procedure. According to the mechanism of photobiomodulation which modulates tissue by regulating cellular activity and increasing microcirculation.²⁴ We suggest that a pre-session of photobiomodulation be considered for improving the quality of post-radiotherapy tissue before undertaking oral surgery intervention. The aPDT has an antimicrobial effect by producing reactive oxygen species.⁶ Furthermore, this mechanism does not cause bacterial resistance.⁶ We postulate that using aPDT may reduce the duration of antibiotic medication taken by the patients.

Strengths and limitations of this review

This is the first systematic review evaluating the effectiveness of laser therapy in preventing ORNJ. However, meta-analysis cannot be performed because there is only one RCT that met the inclusion criteria. Before making a reliable conclusion, we emphasize that there is a need for a well-designed RCT to examine the preventive effect of laser therapy for ORNJ.

Implications for practice

There is limited evidence evaluating the effectiveness of laser therapy alone to prevent ORNJ. However, there is no report of ORNJ and clinical complications after being treated with laser therapy. This study cannot conclude that laser therapy alone prevents ORNJ due to an insufficient number of included studies. With the medium certainty evidence, this study probably recommends that pre-session and post-session of laser therapies combined with antibiotics may prevent ORNJ and promote tissue coverage in the patients who underwent extraction.

Implications for research

We strongly recommend further clinical trials assessing the effectiveness of laser therapy alone or combining the treatment with other preventive modalities to prevent

ORNJ. Not only the clinical outcomes should be evaluated but the patient satisfaction should be assessed among different preventive modalities of ORNJ.

Conclusion

From this systematic review of which low risk of bias and moderate certainty of evidence, there was a possibility of using laser therapy immediately after extraction to prevent ORNJ by gaining faster tissue coverage. In the case reports, it was found some combinations of using laser therapies; photobiomodulation and photodynamic therapy with antibiotics or pentoxifylline and tocopherol or PRF. Using these combinations allowed favourable results in the prevention of ORNJ.

Sources of support: This systematic review was supported by Lasers in Dentistry Research Group (LDRG), Faculty of Dentistry, Khon Kaen University, Thailand.”

Declarations of interest: There is no declaration of interest.

References

1. Alfouzan AF. Radiation therapy in head and neck cancer. *Saudi Med J* 2021;42(3):247–54.
2. Chronopoulos A, Zarra T, Ehrenfeld M, Otto S. Osteoradionecrosis of the jaws: definition, epidemiology, staging and clinical and radiological findings. A concise review. *Int Dent J* 2018;68(1):22–30.
3. Marx RE, Sawatari Y, Fortin M, Broumand V. Bisphosphonate-induced exposed bone (osteonecrosis/osteopetrosis) of the jaws: risk factors, recognition, prevention, and treatment. *J Oral Maxillofac Surg* 2005;63(11):1567–75.
4. Kolokythas A, Rasmussen JT, Reardon J, Feng C. Management of osteoradionecrosis of the jaws with pentoxifylline–tocopherol: a systematic review of the literature and meta-analysis. *Int J Oral Maxillofac Surg* 2019;48(2):173–80.
5. Rice N, Polyzois I, Ekanayake K, Omer O, Stassen LFA. The management of osteoradionecrosis of the jaws - A review. *The surgeon* 2015; 13(2):101–9.
6. Ribeiro GH, Minamisako MC, Rath IB da S, Santos AMB, Simões A, Pereira KCR, et al. Osteoradionecrosis of the jaws: case series treated with adjuvant low-level laser therapy and antimicrobial photodynamic therapy. *J Appl Oral Sci* 2018;26:e20170172.
7. Hwang L, Gung C, Hwang LA, Chang CH, Tai WC, Su WC. Current Management of Osteoradionecrosis of Jaw in Head and Neck Cancer. *Int J Head Neck Sci* 2019;3(2):92–8.

8. Leesomprasong T, Thaweedej S: The effectiveness of hyperbaric oxygen therapy for management osteoradionecrosis in Jaw: A meta-analysis. *J Dept Med Servic* 2021;46(1):100–6.
9. Robard L, Louis MY, Blanchard D, Babin E, Delanian S. Medical treatment of osteoradionecrosis of the mandible by PENTOCLO: Preliminary results. *Eur Ann Otorhinolaryngol Head Neck Dis* 2014;131(6):333–8.
10. Dai T, Tian Z, Wang Z, Qiu W, Zhang Z, He Y. Surgical management of osteoradionecrosis of the jaws. *J Craniofac Surg* 2015;26(2):e175–9.
11. Fritz GW, Gunsolley JC, Abubaker O, Laskin DM. Efficacy of pre- and postirradiation hyperbaric oxygen therapy in the prevention of postextraction osteoradionecrosis: a systematic review. *J Oral Maxillofac Surg* 2010;68(11):2653–60.
12. Aggarwal K, Goutam M, Singh M, Kharat N, Singh V, Vyas S, et al. Prophylactic Use of Pentoxifylline and Tocopherol in Patients Undergoing Dental Extractions Following Radiotherapy for Head and Neck Cancer. *Niger J Surg* 2017;23(2):130-3.
13. El-Rabbany M, Duchnay M, Raziiee HR, Zych M, Tenenbaum H, Shah PS, et al. Interventions for preventing osteoradionecrosis of the jaws in adults receiving head and neck radiotherapy. *Cochrane Database Syst Rev* 2019;2019(11):CD011559.
14. Higgins JPT, Thomas J, Chandler J, Cumpston M, Li T, Page MJ, Welch VA (editors). *Cochrane Handbook for Systematic Reviews of Interventions* version 6.3 (updated February 2022). Cochrane, 2022. Available from www.training.cochrane.org/handbook.
15. Higgins JP, Altman DG, Gøtzsche PC, Jüni P, Moher D, Oxman AD, et al. Cochrane Bias Methods Group; Cochrane Statistical Methods Group. The Cochrane Collaboration’s tool for assessing risk of bias in randomised trials. *BMJ* 2011;343:d5928.
16. Munn Z, Barker TH, Moola S, Tufanaru C, Stern C, McArthur A, et al. Methodological quality of case series studies: an introduction to the JBI critical appraisal tool. *JBI Evid Synth* 2020;18(10):2127-2133.
17. Schünemann HJ, Higgins JP, Vist GE, Glasziou P, Akl EA, Skoetz N, Guyatt GH, Cochrane GRADEing Methods Group (formerly Applicability and Recommendations Methods Group) and the Cochrane Statistical Methods Group. Completing ‘Summary of findings’ tables and grading the certainty of the evidence. *Cochrane Handbook for systematic reviews of interventions* 2019:375-402.
18. Guyatt G, Oxman AD, Akl EA, Kunz R, Vist G, Brozek J, et al. GRADE guidelines: 1. Introduction—GRADE evidence profiles and summary of findings tables. *J Clin Epidemiol* 2011;64(4):383-94.
19. Moreschi C, CAPPARÈ P, Meleti M, Vescovi P, Bonanini M, Gherlone EF, et al. Low level laser therapy in non-surgical management of osteoradionecrosis of the jaws. *Minerva Stomatol* 2016;65(3):185-7.
20. da Silva TMV, Melo TS, de Alencar RC, Pereira JRD, Leão JC, Silva IHM, et al. Photobiomodulation for mucosal repair in patients submitted to dental extraction after head and neck radiation therapy: a double-blind randomized pilot study. *Support Care Cancer* 2021; 29(3):1347-54.
21. Magalhães IA, Forte CPF, Viana TSA, Teófilo CR, Lima Verde RMB, Magalhães DP, et al. Photobiomodulation and antimicrobial photodynamic therapy as adjunct in the treatment and prevention of osteoradionecrosis of the jaws: A case report. *Photodiagnosis Photodyn Ther* 2020;31:101959.
22. Tateno RY, Palma LF, Sendyk WR, Campos L. Laser and antimicrobial photodynamic therapy for the management of delayed healing following multiple dental extractions in a post-radiotherapy patient. *Photodiagnosis Photodyn Ther* 2020;30:101764.
23. Franco T, Cezini M, Metropolo L, Ferreira D, Tannure P: Success of preventive approach to mandibular osteoradionecrosis in an adolescent: case report. *Oral Surg* 2017;10(4):e104-9.
24. Dompe C, Moncrieff L, Matys J, Grzech-LeŚniak K, Kocherova I, Bryja A, et al. Photobiomodulation-Underlying Mechanism and Clinical Applications. *J Clin Med* 2020;9(6):1724.